

SPECIAL ARTICLE

Marginal zone lymphomas: ESMO Clinical Practice Guidelines for diagnosis, treatment and follow-up[☆]

E. Zucca^{1,2,3}, L. Arcaini^{4,5}, C. Buske⁶, P. W. Johnson⁷, M. Ponzoni⁸, M. Raderer⁹, U. Ricardi¹⁰, A. Salar¹¹, K. Stamatopoulos¹², C. Thieblemont¹³, A. Wotherspoon¹⁴ & M. Ladetto¹⁵, on behalf of the ESMO Guidelines Committee*

¹Division of Medical Oncology, Oncology Institute of Southern Switzerland, Bellinzona; ²Department of Medical Oncology, Inselspital, Bern University Hospital, University of Bern, Bern; ³Institute of Oncology Research, Bellinzona, Switzerland; ⁴Division of Hematology, Fondazione IRCCS Policlinico San Matteo, Pavia; ⁵Department of Molecular Medicine, University of Pavia, Pavia, Italy; ⁶Comprehensive Cancer Centre, University Hospital of Ulm, Ulm, Germany; ⁷Cancer Research UK Centre, Southampton General Hospital, Southampton, UK; ⁸Vita-Salute San Raffaele University and Pathology Unit, San Raffaele Scientific Institute, Milan, Italy; ⁹Internal Medicine I, Division of Oncology, Medical University Vienna, Vienna, Austria; ¹⁰Department of Oncology, University of Turin, Turin, Italy; ¹¹Department of Hematology, Hospital del Mar, Barcelona, Barcelona, Spain; ¹²Institute of Applied Biosciences, CERTH, the Centre for Research and Technology Hellas, Thessaloniki, Greece; ¹³Department of Hematology, APHP-Saint-Louis Hospital, University Paris-Diderot, Paris, France; ¹⁴Department of Histopathology, The Royal Marsden Hospital, London, UK; ¹⁵Division of Hematology, Azienda Ospedaliera SS. Antonio e Biagio e Cesare Arrigo, Alessandria, Italy

Key words: marginal zone B-cell lymphoma (MZL), extranodal marginal zone lymphoma (EMZL), splenic marginal zone lymphoma (SMZL), nodal marginal zone lymphoma (NMZL), mucosa-associated lymphoid tissue (MALT), clinical practice guidelines

In the last update of the World Health Organization (WHO) classification, the marginal zone B-cell lymphomas (MZLs) comprise extranodal MZL (EMZL) of mucosa-associated lymphoid tissue (MALT), also known as MALT lymphoma, splenic MZL (SMZL) with or without villous lymphocytes and nodal MZL (NMZL) with or without monocytoid B cells. These are three distinct clinical entities with specific diagnostic criteria and different genetic features, clinical behaviour and therapeutic implications.^{1–3} The onset of an overt MZL, particularly of SMZL, may be preceded by the appearance of clonal B cells in the blood, a condition recently described as clonal B-cell lymphocytosis of marginal zone origin (CBL-MZ).⁴

INCIDENCE AND EPIDEMIOLOGY

MZLs represent approximately 5%–15% of all non-Hodgkin lymphomas in the Western world. EMZLs comprise approximately two-thirds and can arise at any extranodal site, usually in the context of chronic antigenic stimulation due either to infections or autoimmune disorders. The stomach is the most common site, followed by ocular adnexa, lung and salivary glands. SMZL accounts for ~20% and NMZL for <10% of cases. Aetiological heterogeneity is apparent across the anatomical sites, probably influenced by either intrinsic genetic/molecular characteristics or geographical factors and

environmental exposures. Overall, the incidence appears to have increased in the last two decades (possibly because of improved pathological diagnosis), despite a decline in the incidence of *Helicobacter pylori*-associated gastric MZLs.⁵

DIAGNOSIS AND PATHOLOGY/MOLECULAR BIOLOGY

The diagnosis should follow the current 2017 WHO classification and requires an adequate tumour biopsy [IV, A]. The typical (centrocyte-like) marginal zone B cells have small- to medium-sized, slightly irregular nuclei with inconspicuous nucleoli, moderately dispersed chromatin and pale cytoplasm. The accumulation of abundant pale-staining cytoplasm may lead to a monocytoid appearance.³ Differential diagnosis from mimics of MZL mainly depends upon immunohistochemistry (IHC), including at least CD20, CD10, CD5, CD23, cyclin D1, immunoglobulin (Ig) D and SOX-11 [IV, B] (Table 1). It is recommended that diagnostic and follow-up biopsies of MZL should be reviewed and confirmed by an expert haematopathologist.⁶ Although there are no entirely definitive criteria, a diagnosis of evolution to large B-cell lymphoma should be made when there are clearly separated sheets of large cells comprising >20% of the neoplastic population [V, B].

CBL-MZ

This condition is defined by the presence of circulating clonal B cells with phenotypic features consistent with a marginal zone origin in the absence of splenomegaly, hepatomegaly, lymphadenopathy or other symptoms and signs suggestive of an established lymphoma. Unlike chronic

*Correspondence to: ESMO Guidelines Committee, ESMO Head Office, Via Geneva 4, CH-6900 Lugano, Switzerland

E-mail: clinicalguidelines@esmo.org (ESMO Guidelines Committee).

[☆]Approved by the ESMO Guidelines Committee: December 2006, last update July 2019. This publication supersedes the previously published version—*Ann Oncol.* 2013;24(suppl. 6):vi144-vi148.

0923-7534/© 2019 European Society for Medical Oncology. Published by Elsevier Ltd. All rights reserved.

Table 1. Immunohistochemical and molecular markers in MZL

Molecule	Type of test	Expected result	Level of recommendation
CD20	IHC	Positive	Mandatory
CD5	IHC	Negative ^a	Mandatory
CD23	IHC	Negative/positive	Suggested ^b
CD10	IHC	Negative	Mandatory
IgD	IHC	Negative ^c	Suggested
Cyclin D1	IHC	Negative	Mandatory ^d
<i>MYD88</i> mutation	PCR	Negative	Suggested ^e

IgD, immunoglobulin D; IHC, immunohistochemistry; LPL, lymphoplasmacytic lymphoma; MZL, marginal zone lymphoma; PCR, polymerase chain reaction; SMZL, splenic marginal zone lymphoma.

^a Few exceptions may occur.

^b In cases with small cell morphology, irrespectively of CD5-concurrent positivity.

^c In cases with splenomegaly, as it is usually positive in SMZL.

^d In cases positive for CD5.

^e When present, a differential diagnostic problem with LPL arises (cases of MZL with *MYD88* mutation may represent rare exceptions).

lymphocytic leukaemia (CLL)-like monoclonal B-cell lymphocytosis (MBL) which may precede the development of CLL, there is no defined cut-off in the clonal B-cell lymphocyte count for discriminating CBL-MZ from MZL. Only a minority (15%–20%) of patients will eventually progress to an overt lymphoma, most often an SMZL.⁴

EMZL

Lymphoepithelial lesions are neither essential for the diagnosis of EMZL nor absolutely specific for this entity, as they can be seen in some reactive conditions as well as in other lymphoma subtypes.

In gastric MZL, if the presence of active *H. pylori* infection is not demonstrated by (immuno)histochemistry, it must be ruled out by serology, urea breath test and/or stool antigen test.⁷

In addition to routine histology and IHC, fluorescent *in situ* hybridisation (FISH) studies for detection of *t(11;18)(p21;p21)* may be useful for identifying gastric MZL patients who are unlikely to respond to antibiotic therapy [III, B].⁵

SMZL

In most instances, the diagnosis of splenic small B-cell lymphomas of marginal origin, usually SMZL, can be established without a splenectomy specimen, through a combination of peripheral blood/bone marrow aspirate morphology and flow cytometry, as well as bone marrow biopsy histology and IHC, reviewed by expert haematopathologists/haematologists [IV, B].^{2,8,9} However, the accuracy and reproducibility of this approach have not yet been fully investigated. In a minority of cases, the definitive diagnosis may not be possible without splenectomy. The same holds for the definitive differential diagnosis between SMZL and splenic diffuse red pulp lymphoma, as they share similar features in the peripheral blood and bone marrow.^{10,11} Neoplastic lymphocytes in SMZL often display villi; however, these are not seen in all cases (sometimes for technical reasons) and not every lymphoma displaying villi corresponds to SMZL.²

NMZL

NMZL shares morphological and immunophenotypic similarities with other MZLs, and its differential diagnosis from other indolent lymphomas can be particularly difficult, unless so-called 'monocytoid B-cell morphology' is prominent. A small monoclonal component, usually IgM, may be detected and, in such cases, differential diagnosis from lymphoplasmacytic lymphoma (LPL) may be necessary. Since *MYD88* gene mutations are detected in the large majority of LPLs, this molecular aberration may be used for diagnostic purposes, with the knowledge that MZLs rarely harbour *MYD88* mutations.¹²

In all cases, but particularly for NMZL, the histopathological diagnosis must be established with full knowledge of the clinical and radiological presentation [IV, A].

NMZL is also seen in children. Notably, paediatric NMZL has distinct morphological and clinical characteristics. It is much more common in boys, usually presents as asymptomatic and localised disease and has a much better prognosis than adult-onset cases.¹

STAGING AND RISK ASSESSMENT

Initial work-up

Mandatory initial staging for all MZL subtypes should include:

- history and physical examination, noting lymph node regions, eyes and ears, nose and throat, liver and spleen;
- full blood and differential counts, with flow cytometry of peripheral blood mandatory in NMZL and SMZL and optional in EMZL;
- biochemistry, including renal and liver function tests;
- protein electrophoresis;
- lactate dehydrogenase (LDH) and β_2 microglobulin (B2M);
- optional direct antiglobulin (Coombs) test in SMZL;
- serum and urine immunofixation;
- serology for hepatitis C virus (HCV) [if positive, including HCV-RNA polymerase chain reaction (PCR) test and virus genotyping];
- cryoglobulins and cryocrit if HCV-positive;
- hepatitis B virus (HBV) markers and human immunodeficiency virus (HIV) serology.

Bone marrow aspirate (with morphology and flow cytometry) and biopsy are mandatory in NMZL and SMZL and highly recommended in EMZL, particularly in non-gastric lymphoma and when only local treatment is planned.

Imaging should include complete chest and abdominal computed tomography (CT) scan [or magnetic resonance imaging (MRI)] and imaging of the orbits and salivary glands [IV, B].

Positron emission tomography (PET) scanning has generally been considered of little clinical utility; however, this is now being reconsidered as a result of the increased sensitivity of modern PET-CT equipment. It may be useful in

cases when only localised treatment is planned. PET scanning should also be considered when clinical and/or laboratory data suggest transformation to high-grade histology and to guide decisions on which lymph node to target for biopsy [IV, B].

Endoscopic ultrasound (US) for gastric MZL can be used to define gastric wall infiltration and perigastric lymph node involvement.

EMZL. EMZL usually remains localised for a prolonged period within the tissue of origin, but involvement of regional lymph nodes and multiple mucosal sites may be present at diagnosis. Within the stomach, the disease is usually multifocal. Concomitant involvement of multiple mucosal sites is not rare, particularly in non-gastric EMZLs, with disseminated disease reported in 25%–50% of cases. Bone marrow infiltration has been described in 2%–20% of cases, with lower rates in recent series, and is more common in non-gastric lymphomas.¹³ EMZLs with lymph node or bone marrow involvement at presentation carry a worse prognosis, but this is not the case for those with involvement of multiple mucosal sites.¹⁴

The best system for staging of gastric MZL is controversial.^{6,7} The Lugano staging system has been widely used previously, but more modern systems have been proposed, such as the Paris staging system which describes the depth of gastric wall involvement more accurately, a parameter that may predict the response to *H. pylori* eradication (Table 2).^{7,15}

The initial staging procedures must take into account the specific site of presentation (Table 3) and for gastric MZL must include an oesophagogastroduodenoscopy (EGD) with multiple biopsies taken from each region of the stomach, duodenum and gastroesophageal junction and from any site with an abnormal appearance. Routine EGD may also be advisable for patients with non-gastrointestinal MZL, particularly females, those with primary involvement of lung, upper airways and salivary glands and those with a high International Prognostic Index (IPI) score, elevated serum B2M level or *H. pylori* infection, regardless of the primary site.^{16,17}

SMZL. SMZL typically involves the spleen, hilar lymph nodes, bone marrow and, frequently, the blood. Some patients are diagnosed following the incidental finding of a peripheral lymphocytosis. In advanced-stage SMZL, symptomatic splenomegaly and cytopaenia may be the presenting features.^{18–20} Some cases of disseminated MZL may present with splenomegaly and lymph node enlargement at distant sites. Approximately 20% of patients have autoimmune manifestations including autoimmune haemolytic anaemia (AIHA), immune thrombocytopaenia, cold agglutinin disease, circulating anticoagulants, acquired von Willebrand disease or angioedema as a result of acquired C1-esterase inhibitor deficiency.

The role of PET is uncertain and SMZL is usually staged by CT. Abdominal sonography may give additional information to CT scanning for the detection of splenic focal lesions.^{21,22} PET-CT should be considered if high-grade transformation is suspected.

NMZL. NMZL usually presents with disseminated lymphadenopathy (mostly cervical and abdominal), with or without bone marrow and blood involvement at diagnosis. The disease is often advanced at presentation and 10%–20% of patients present with B symptoms (unexplained weight loss >10% in 6 months, unexplained fever >38°C, drenching night sweats). Anaemia occurs in ~25% of patients and thrombocytopaenia in 10%. Initial staging follows the rules for other nodal lymphomas, with the main goal to discriminate localised from advanced-stage disease and to have measurable disease for evaluation of treatment response.^{21–23} Staging should rule out primary EMZL, since around one-third of cases represent nodal dissemination of an EMZL.^{21,24}

Main prognostic factors and prognostic indices

EMZL. The International Extranodal Lymphoma Study Group (IELSG) has developed an EMZL-specific prognostic index using data from more than 400 patients enrolled in a large prospective randomised trial. This index, named MALT-IPI, uses three simple clinical parameters (age ≥70 years, Ann Arbor stage III or IV and elevated LDH) and allows the

Table 2. Comparison of the Lugano and Paris staging systems for gastrointestinal tract lymphoma^{7,16}

	Lugano staging system	Paris staging system	Tumour extension
Stage I	Confined to the GI tract (single primary or multiple, non-contiguous)	T1m N0 M0 T1sm N0 M0 T2 N0 M0 T3 N0 M0	Mucosa Submucosa Muscularis propria Serosa
Stage II	Extending into abdomen		
II1	Local nodal involvement	T1–3 N1 M0	Perigastric lymph nodes
II2	Distant nodal involvement	T1–3 N2 M0	More distant regional nodes
Stage IIE	Penetration of serosa to involve adjacent organs or tissues	T4 N0–2 M0	Invasion of adjacent structures with or without abdominal lymph nodes
Stage IV	Disseminated extranodal involvement or concomitant supra-diaphragmatic nodal involvement	T1–4 N3 M0 T1–4 N0–3 M1 T1–4 N0–3 M2	Extra-abdominal lymph nodes Distant (non-contiguous) GI sites involvement Non-GI sites involvement

GI, gastrointestinal.

T describes the gastric wall infiltration; N describes the regional lymph node involvement; M describes distant dissemination.

Adapted from Ruskone-Fourmestreaux et al.⁷ and Mazloom et al.¹⁶

Table 3. Specific staging and work-up procedures for EMZL at different primary anatomic sites

Site	Exam	Notes
Stomach	EGD	Mandatory
	Endoscopic US	Optional, to evaluate the regional lymph nodes and gastric wall infiltration
	IHC	Mandatory, to evaluate <i>Helicobacter pylori</i> status. Faecal antigen or breath test and serology studies are recommended when the results of histology are negative
	FISH or PCR assay	Optional, to detect <i>t(11;18)</i> translocation
Small intestine (IPSID)	PCR, IHC or ISH	<i>Campylobacter jejuni</i> search in the tumour biopsy
Colon	Colonoscopy and EGD	
Ocular adnexa	Orbital and salivary glands imaging (MRI or CT)	If clinically indicated
	Head and neck imaging (MRI or CT)	If clinically indicated
	PCR	<i>Chlamydomphila psittaci</i> search in the tumour biopsy and PBMCs (optional, according to the geographical distribution of the infection)
Salivary glands	ENT examination and echography	
	EGD	
	Anti-SSA/Ro and anti-SSB/La antibodies	To rule out association with Sjogren syndrome
Lung	Bronchoscopy and bronchoalveolar lavage	
	EGD	
Breast	Mammography and breast sonography	
	MRI (or CT scan)	
Thyroid	Thyroid echography	
	CT scan of the neck	
	Thyroid function tests	
Skin	PCR	<i>Borrelia burgdorferi</i> search in the tumour biopsy

CT, computed tomography; EGD, oesophagogastrroduodenoscopy; EMZL, extranodal marginal zone B-cell lymphoma; ENT, ear, nose and throat; FISH, fluorescent *in situ* hybridisation; IHC, immunohistochemistry; IPSID, immunoproliferative small intestinal disease; ISH, *in situ* hybridisation; MRI, magnetic resonance imaging; PBMC, peripheral blood mononuclear cell; PCR, polymerase chain reaction; US, ultrasound.

discrimination of three groups of patients with low, intermediate and high risk (corresponding to the presence of 0, 1 or ≥ 2 of these factors, respectively). The 5-year event-free survival rates in these groups were 70%, 56% and 29%, respectively. The MALT-IPI distinguished patients with different progression-free, overall and cause-specific survival. Its prognostic utility was retained in gastric and non-gastric lymphomas, as well as in patients treated with different modalities, and was confirmed in a large external validation set of more than 600 patients.²⁵ However, there are no data yet to indicate that the choice of therapy should be based on this index.

SMZL. An Italian lymphoma cooperative group (Intergruppo Italiano Linfomi; IIL) developed a prognostic model in more than 300 patients based on three risk factors (haemoglobin <12 g/dl, albumin <35 g/l and elevated LDH level).²⁶ A newer prognostic model (named HPLL on the basis of the determinant factors: haemoglobin concentration, platelet count, LDH level and extrahilar lymphadenopathy) has been developed by the SMZL Study Group from an international retrospective survey of nearly 600 patients²⁷ and identified three risk groups with significantly different outcomes [IV, C]. A simplified version of the HPLL was later proposed and validated.^{28,29} Analogous to the MALT-IPI, there is no evidence supporting the use of these indices to decide whether and which therapy should be given.

NMZL. There is no specific prognostic score established for NMZL. The Follicular Lymphoma International Prognostic Index (FLIPI), although not validated for NMZL, may help

discriminate between low- and high-risk patients in smaller patient cohorts.²⁴

TREATMENT

EMZL

Initial therapy with antibiotics in gastric MZL. *Helicobacter pylori* eradication therapy should be given to all patients with gastric MZL, irrespective of stage [II, A].^{5–7,30,31} Anti-*H. pylori* regimen should be chosen based on the regional microbial ecology; usually triple-therapy regimens combining a proton-pump inhibitor (PPI) for 4 weeks plus clarithromycin with either amoxicillin or metronidazole for 10–14 days are highly effective.^{32,33} The outcome of eradication therapy should be checked by a urea breath test (or by a monoclonal stool antigen test) at least 6 weeks after starting eradication therapy and at least 2 weeks after PPI withdrawal. Where *H. pylori* eradication is not successful, second-line treatment should be attempted with alternative triple- or quadruple-therapy regimens of PPI plus antibiotics.^{5,7,30,31}

In localised *H. pylori*-positive gastric MZL, the initial treatment should be *H. pylori* eradication. This treatment can induce lymphoma regression and long-term clinical disease control in three-quarters of patients [II, A]. The length of time necessary to obtain a remission can vary from a few weeks to more than a year. In patients who achieve clinical and endoscopic remission with eradication of *H. pylori* but have persistent microscopic lymphoma on histology, it is reasonable to wait for at least 12 months

before starting another treatment [III, B].^{5,7} Several studies of post-antibiotic molecular follow-up have shown the frequent persistence of monoclonal B cells after histological regression of the lymphoma.^{5,7}

In *H. pylori*-negative cases, regression of the lymphoma after antibiotic treatment is less likely and the immediate start of specific anti-lymphoma treatments (see below) may be considered. A trial of anti-*Helicobacter* therapy may still be worthwhile, since occasional lymphoma responses have been reported, possibly due to a false-negative test or infection by other *Helicobacter* species [IV, C].^{7,34} In these *H. pylori*-negative patients, specific treatment [usually radiotherapy (RT) as described below] should be considered if no signs of lymphoma regression are seen at a repeat endoscopy assessment 3–6 months after antibiotic therapy.

Figure 1 summarises the recommended treatment algorithm for localised gastric MZL. After anti-*H. pylori* treatment, the patients presenting with advanced disease (stage IV) can be managed expectantly (watch-and-wait) unless systemic treatment (see 'Other treatments for EMZL') is required because of symptomatic disease. Any treatment decision should also take into account the patient's preference (Figure 2).

Anti-infective therapy in non-gastric EMZL. Eradication therapy with antibiotics in EMZL arising outside the stomach remains investigational. While *H. pylori* eradication is not recommended for extra-gastric MZL, various results suggest the involvement of other infectious agents, especially in ocular adnexal EMZL. As response rates up to 65% with long-lasting complete remissions have been reported, antibiotic therapy may be considered for initial therapy in patients with ocular EMZL, if they are not in need of urgent treatment to preserve their sight.³⁵

Recent results have shown that therapy of HCV infection may lead to regression of lymphoma in patients with HCV-associated EZML, suggesting that these (rare) patients should also be given anti-HCV drugs as initial therapy of EZML [IV, B].³⁶

RT in localised EMZL: recommended doses and schedules at different sites. In patients who do not achieve lymphoma regression following antibiotic therapy, irradiation and systemic oncological therapies should be used, depending on the stage of disease. RT is the preferred option for treatment of localised disease. Excellent disease control using RT alone has been reported in several series, supporting the use of moderate-dose (e.g. 24–30 Gy to the stomach and perigastric nodes, given over 3–4 weeks) involved-field RT (IFRT) in gastric EMZL [II–IV, A–B].^{37,38} A phase III trial from the UK has further shown that the dose of RT can be safely lowered to 24 Gy in indolent lymphomas, including those of MALT, without compromising local tumour control in the long term [II, A].³⁹

A recent guideline from the International Lymphoma Radiation Oncology Group (ILROG) clearly describes the volumes to be treated for each site of extranodal lymphomas, including MALT, in respect of the modern definition of involved-site RT (ISRT).⁴⁰

Long-term complications related to irradiation of EMZL are rare, dose-dependent and predominantly related to orbital irradiation. There is an increased risk of cataract and dry eyes for doses >4–5 Gy, while ischaemic retinopathy, optic atrophy, corneal ulceration and glaucoma are uncommon for doses below 36 Gy. More recently, low-dose RT (4 Gy in two fractions) has been increasingly used in the management of indolent non-Hodgkin lymphomas, with progression-free survival (PFS) rates of ~70% at 5 years.⁴¹ This fractionation may be extremely useful in particular anatomical presentations, such as ocular adnexa lymphomas, where the lower dose reduces the risk of cataract while maintaining high response rates (96%) and durable local control (96% at 2 years), as shown by a retrospective study from the United States.⁴² The standard recommended dose still remains 24 Gy, but a low-dose schedule (4 Gy) may also be considered in the elderly or in the setting of a palliative treatment for patients with advanced-stage EMZL unfit for systemic therapy or in critical sites (considering the possibility to deliver the standard dose in case of no response to 4 Gy).

Other treatments for EMZL. Chemotherapy (ChT), immunotherapy, or combination chemoimmunotherapy are all effective in patients with EMZL who require systemic treatment. Usually, systemic treatment is preferred in patients with symptomatic systemic disease, contraindications to RT, failure after antibiotics or after local therapy (RT or surgery), and also in those with histological transformation (Figure 2).^{5,7,43}

Relatively few compounds and regimens have been tested specifically in EMZLs. Hence, patients should be offered enrolment in clinical trials where available. As in other indolent lymphomas, alkylating agents (either cyclophosphamide or chlorambucil) or purine nucleoside analogues (fludarabine, cladribine) have shown activity [III, B].^{44,45}

The efficacy of rituximab in combination with chlorambucil has been proven in a large randomised phase III study [I, A].⁴⁶ This combination was well tolerated and improved complete response rate (CRR), event-free survival and PFS compared with either rituximab or chlorambucil as single agents, although no overall survival (OS) benefit was seen. Since the efficacy of rituximab monotherapy has also been demonstrated in phase II studies, its use can be considered when the potential toxicity of ChT is a relevant issue [III, B].^{47–49}

A phase II study of the combination of rituximab and bendamustine has shown good activity, including in cases carrying *t(11;18)*. Most patients achieve a complete remission after 4 cycles of this combination and it may be possible to stop treatment at this point,^{50,51} thereby avoiding the greater toxicity of longer schedules [III, A]. The need for rituximab maintenance is controversial, with no evidence of OS benefit^{52,53} and there are no published data supporting rituximab maintenance [III, D].

Consolidation therapy with chlorambucil is not beneficial in patients with gastric lymphoma responding to *H. pylori* eradication [II, D].⁵⁴

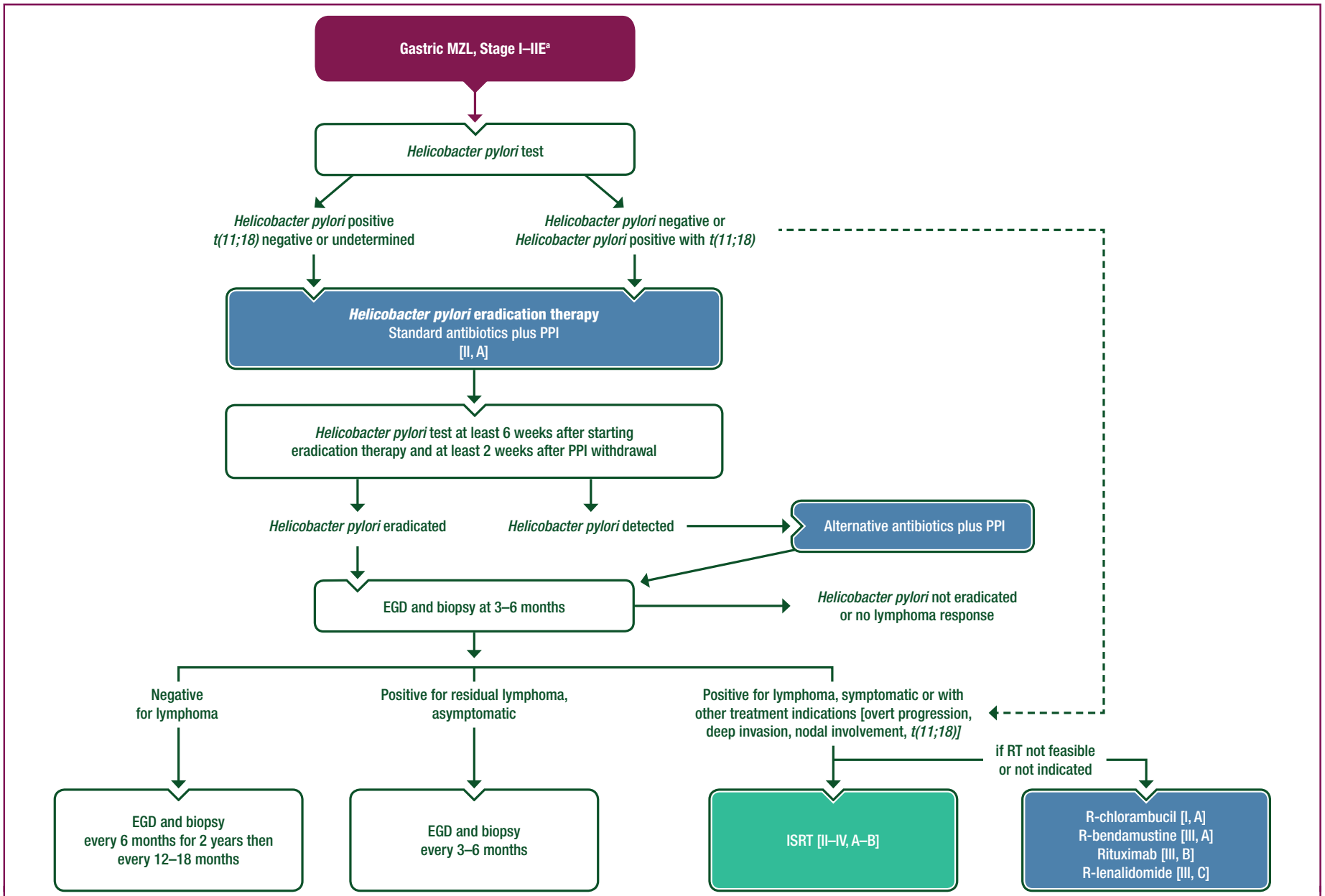


Figure 1. Treatment algorithm for localised gastric MZL.

EGD, oesophagogastroduodenoscopy; ISRT, involved-site radiotherapy; MZL, marginal zone B-cell lymphoma; PPI, proton-pump inhibitor; R, rituximab; RT, radiotherapy.

^a Stage is defined according to the Lugano staging system described in Table 2.

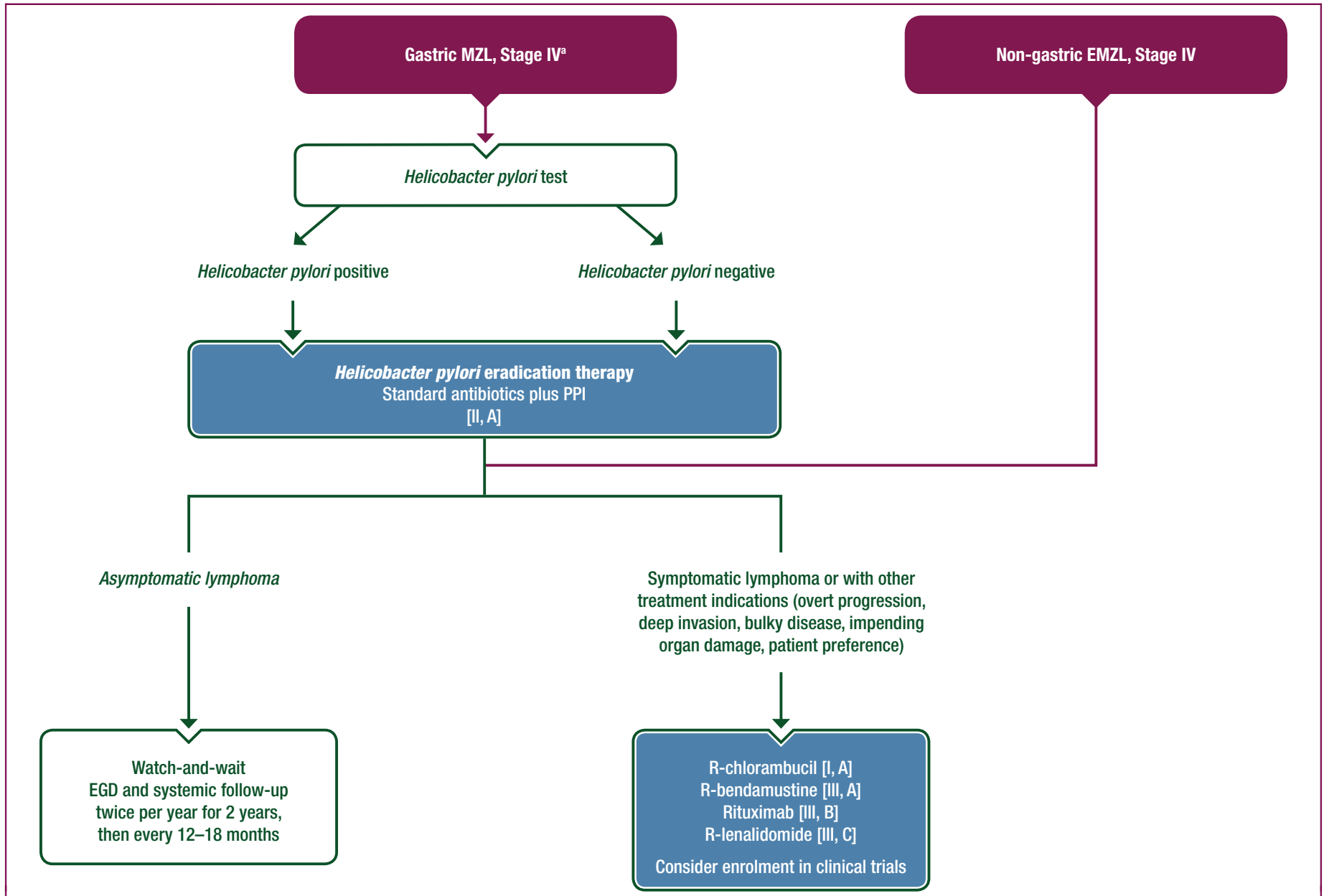


Figure 2. Treatment algorithms for advanced gastric MZL and non-gastric EMZL.

EGD, oesophagogastrroduodenoscopy; EMZL, extranodal marginal zone B-cell lymphoma; MZL, marginal zone B-cell lymphoma; PPI, proton-pump inhibitor; R, rituximab.

^a Stage is defined according to the Lugano staging system described in Table 2.

Rituximab in combination with lenalidomide has shown promising activity in a phase II study, with an acceptable toxicity profile [III, C].⁵⁵

Lymphomas carrying the *t(11;18)* are usually unresponsive to alkylating agents as sole treatment but are sensitive to purine analogues or rituximab.^{5,7}

The combination of rituximab and fludarabine has shown noteworthy activity in EMZLs^{56,57} but there are risks of significant immunotoxicity and secondary myelodysplasia [III, C].

Anthracycline-containing regimens are not usually necessary and should be reserved for the few patients with a very aggressive clinical course with suspected histological transformation [IV, A].⁴³ Cases with proven histological transformation should be treated with chemoimmunotherapy according to the guidelines for diffuse large B-cell lymphoma [II, A].⁵⁸

Surgery has not been shown to achieve superior results than less invasive approaches in EMZL. It may impair the quality of life, and procedures such as gastrectomy no longer have a role in the initial treatment of EMZL.^{59,60}

SMZL

In asymptomatic patients, an active surveillance (watch-and-wait) policy is recommended, with follow-up evaluation every 3–6 months (physical exam, abdominal US, blood count and biochemistry).

In patients with concomitant chronic HCV infection who do not immediately need conventional treatment, antiviral therapy should be considered [IV, B].^{22,36,61}

The main criteria for initiating treatment in SMZL are the presence of progressive or symptomatic splenomegaly and/or any progressive cytopenias (haemoglobin <10 g/dl, platelets <80 000/ μ l, neutrophils <1000/ μ l). Autoimmune disorders such as AIHA or idiopathic thrombocytopenic purpura, if present, should be specifically treated [V, B].

For SMZL, the recognised therapeutic options are splenectomy,^{18,62,63} ChT,^{22,64,65} rituximab alone^{66–68} or rituximab plus ChT.^{22,65,66,69}

Splenectomy was traditionally considered as the recommended first treatment for patients with SMZL. The majority of patients who had a splenectomy showed haematological responses with restoration of cytopenias and a fast resolution of splenomegaly-related symptoms. The 5-year PFS and OS are 50%–60% and 70%–80%, respectively, and approximately half of the splenectomised patients did not require further treatment for SMZL.^{70,71} However, it is a major surgical procedure that may have severe, and potentially fatal, acute and late complications. Moreover, splenectomy cannot completely eradicate the disease and has been largely replaced by rituximab (with or without ChT) in the last two decades as the preferred initial therapy [III, A].⁷²

Rituximab therapy alone (375 mg/m² 4- to 8-weekly doses) can produce a rapid response, with a high overall response rate (>80%) and CRR (>40%) with minimal toxicity. Responses to rituximab appear to be long lasting, with a 10-year PFS exceeding 60%.⁷⁰ Maintenance with rituximab (every 2 months for 1–2 years) may improve PFS

but no OS advantage has been shown to date and maintenance may not be superior to retreatment on demand.⁷⁰ Rituximab usually remains active at relapse.

Rituximab can be particularly useful in patients with autoimmune disorders, since it can allow concomitant control of AIHA (or idiopathic thrombocytopenic purpura) and lymphoma, thereby avoiding the toxicity of long-term steroid administration.

For the patients who do not respond to rituximab, splenectomy [IV, B] or the addition of ChT may be considered. Chemoimmunotherapy is particularly indicated for fit patients with symptomatic disseminated disease, constitutional symptoms and/or signs of high-grade transformation [III, B].

NMZL

Treatment should follow the principles of therapy for follicular lymphoma [IV, B]. In advanced-stage NMZL with low tumour burden and lack of clinical symptoms, a watch-and-wait strategy may be followed. Treatment should be initiated in the case of B symptoms, deterioration of peripheral blood counts due to lymphoma infiltration of the bone marrow, rapid enlargement of lymph nodes or compression of vital organs by bulky disease. RT should be considered in patients presenting with localised disease.

Rituximab combined with ChT is the backbone of treatment. There are different options for ChT including rituximab/bendamustine, rituximab/cyclophosphamide/doxorubicin/vincristine/prednisone (R-CHOP), rituximab/cyclophosphamide/vincristine/prednisone (R-CVP) or rituximab/fludarabine. Fludarabine combined with rituximab, however, was associated with high treatment-related toxicity.⁵⁷ Rituximab/bendamustine followed by rituximab maintenance was associated with higher treatment-related mortality than R-CHOP in a large randomised phase III trial, comprising 195 treatment-naïve patients with MZL (66 with NMZL), along with patients with follicular lymphoma.⁷³ Thus, the choice of the ChT partner should be adapted to the individual fitness of the patient and the risk of infections. Rituximab maintenance is optional, as there is no evidence from prospective randomised studies that this is superior to observation after successful induction in NMZL.⁷⁴ In patients with NMZL and concurrent HCV-related chronic hepatitis, antiviral treatment may induce remission in a high proportion of cases. In patients not needing immediate lymphoma treatment, antiviral therapy should be considered as first treatment [IV, B].^{36,61}

MZL patients with recurrent disease

Asymptomatic patients may be observed (watch-and-wait) and RT may be considered for MZL patients with localised relapses.⁶¹ If systemic treatment is required, chemoimmunotherapy can be repeated after long initial remissions (\geq 24 months). Autologous transplantation may be considered in fit patients with clinically aggressive relapse. In other cases, an alternate chemoimmunotherapy regimen can be used. In a phase II trial, ibrutinib single-agent

Table 4. GELA grading system proposed to define the histological response of gastric MZL after *Helicobacter pylori* eradication⁷²

Response (score)	Description	Histological characteristics
CR	Complete histological remission	Normal or empty LP and/or fibrosis with absent or scattered plasma cells and small lymphoid cells in the LP, no LEL
pMRD	Probable minimal residual disease	Empty LP and/or fibrosis with aggregates of lymphoid cells or lymphoid nodules in the LP/MM and/or SM, no LEL
rRD	Responding residual disease	Focal empty LP and/or fibrosis with dense, diffuse or nodular lymphoid infiltrate, extending around glands in the LP, focal LEL or absent
NC	No change	Dense, diffuse or nodular lymphoid infiltrate, LEL usually present

GELA, Groupe d'Etude des Lymphomes de l'Adulte; LEL, lymphoepithelial lesion; LP, lamina propria; MM, muscularis mucosa; MZL, marginal zone B-cell lymphoma; SM, submucosa.

Reprinted from Kalpadakis et al.⁷² with permission.

therapy showed anti-lymphoma activity in MZL including NMZL, leading to approval of the drug in the United States for the treatment of patients with MZL who require systemic therapy and have received at least one prior anti-CD20-based therapy.⁷⁵ The phosphoinositide 3-kinase (PI3K) inhibitor copanlisib had also demonstrated significant efficacy and a manageable safety profile in heavily pretreated patients with relapsed or refractory MZL.⁷⁶ Thus, these targeted agents may become a treatment option, in particular for patients with short remissions after rituximab-containing chemoimmunotherapy [III, B].⁷⁵

RESPONSE EVALUATION AND FOLLOW-UP

General considerations

Asymptomatic patients with disseminated MZL (SMZL and NMZL) being managed expectantly (watch-and-wait) should be monitored by physical examination, imaging as clinically required, blood counts and biochemistry every 6 months. The interval between visits may be shortened when there is increasing splenomegaly, lymphadenopathy, cytopaenias and/or symptoms related to the disease. A CT scan or bone marrow biopsy is not indicated unless there are signs of disease progression.

Fluorodeoxyglucose (FDG)-PET investigation can be considered in selected cases when there are clinical and/or

laboratory findings to suggest possible histological transformation. PET scans should also be carried out in cases where transformation has been demonstrated, for staging.

Patients with EMZL at non-gastric sites who have completed treatment can be re-evaluated in the same way as any other indolent lymphoma (clinical examination, laboratory work-up, imaging/biopsy of residual lesions if indicated) every 3 months for the first 2 years, and every 6 months thereafter.

Gastric MZL

Sequential evaluation of gastric biopsies remains an essential follow-up procedure for gastric MZL to exclude either persistent disease or the appearance of early epithelial changes which may lead to gastric carcinoma, particularly in patients with persistent *H. pylori* infection. Unfortunately, the interpretation of lymphoid infiltrates in post-treatment gastric biopsies can be very difficult and there are no uniform criteria for the definition of histological remission. Comparison with previous biopsies is helpful to assess response, and the authors recommend the Groupe d' Etude des Lymphomes de l' Adulte (GELA) scoring system (Table 4) as a reproducible method [IV, B].⁷⁷

Following the documentation of *H. pylori* eradication, strict endoscopic follow-up is recommended, with multiple biopsies taken 2–3 months after treatment to rule out tumour progression, and subsequently (twice per year for 2 years) to monitor the histological regression of the lymphoma.

Gastric MZLs have a limited tendency to distant spread and to histological transformation. Transient, apparent histological relapses are occasionally observed in endoscopic follow-up biopsies but are considered a relapse only if they are sustained and progressive, as they are often self-limiting, especially in the absence of *H. pylori* reinfection. Hence, in the case of persistent but stable residual disease or histological relapse (without distant dissemination and/or gross endoscopic tumour), a watch-and-wait policy appears to be safe [IV, C].^{78–80}

Nevertheless, long-term endoscopic and systemic follow-up (clinical examination, blood counts every 12–18 months) is recommended. The risk of gastric adenocarcinoma among patients diagnosed with gastric MZLs has been reported to be six-fold higher than in the general population, although it still remains relatively low,⁸¹ and the

Table 5. Response criteria for SMZL

Complete response	Resolution of organomegaly (spleen longitudinal diameter <13 cm) Hb >12 g/dl, platelets >100 × 10 ⁹ /l and neutrophils >1.5 × 10 ⁹ /l No evidence of circulating clonal B cells by flow cytometry (light chain-restricted B cells) No evidence of bone marrow infiltration detected by IHC Negative DAT and PET (if positive at diagnosis)
Partial response	Regression ≥50% in all the measurable disease manifestations No new sites of disease Improvement of cytopaenias Decrease of infiltration and improvement of haematopoietic reserve at bone marrow biopsy
No change	<10% Improvement on the disease manifestations Colonoscopy and EGD
Progression	>50% measurable signs of the disease from nadir
Relapse	Reappearance of any measurable sign of the disease

DAT, direct antiglobulin test; EGD, oesophagogastrroduodenoscopy; Hb, haemoglobin; IHC, immunohistochemistry; PET, positron emission tomography; SMZL, splenic marginal zone lymphoma.

Table 6. Summary of recommendations**Staging and risk assessment**

- Initial staging for all MZL subtypes should include history and physical examination, full blood and differential counts, biochemistry including renal and liver function tests, protein electrophoresis, LDH and B2M, serum and urine immunofixation, serology for HBV, HCV and HIV and cryoglobulins and cryocrit if HCV-positive
- IHC panel including at least CD20, CD10, CD5, CD23, cyclin D1 and IgD with diagnostic evaluation by an expert haematopathologist [IV, B]
- Clinical and biological prognosticators (HPLL, MALT-IPI) should be applied in clinical routine to estimate the clinical behaviour [III–IV, C]

Treatment**EMZL**

- *Helicobacter pylori* eradication therapy should be given to all patients with gastric MZL [II, A]
- ISRT is the preferred option for treatment of localised EMZL (moderate dose, which may vary according to the site) [II–IV, A–B]
- Anti-HCV therapy is recommended in patients with HCV-associated lymphoma [IV, B]
- Other treatments including ChT, immunotherapy or combination chemoimmunotherapy are indicated in patients with symptomatic disseminated disease, contraindications to RT, failure after antibiotics or after local therapy or clinical suspicion of histological transformation: R-chlorambucil [I, A], R-bendamustine [III, A], rituximab monotherapy [III, B], R-lenalidomide [III, C] and R-CHOP for (clinically suspected or biopsy-proven) histological transformation

SMZL

- Rituximab alone is the preferred initial therapy in patients with SMZL [III, A]
- Chemoimmunotherapy is indicated when rituximab alone is ineffective or in the presence of disseminated symptomatic disease and/or signs of high-grade transformation [III, B]
- Anti-HCV therapy should be considered in patients with HCV-associated lymphoma [IV, B]
- Splenectomy may be considered in selected cases, when rituximab is not indicated or ineffective [IV, B]

NMZL

- Treatment should follow the principles of therapy for follicular lymphoma [IV, B]
- Anti-HCV therapy should be considered in patients with HCV-associated lymphoma [IV, B]
- Chemoimmunotherapy is recommended in patients with NMZL (e.g. R-bendamustine, R-CHOP, R-CVP) [IV, B]

Response evaluation and follow-up

- Asymptomatic patients with disseminated MZL (SMZL and NMZL) being managed by watch-and-wait should be monitored by physical examination, imaging as clinically required, blood counts and biochemistry every 6 months
- Patients with EMZL at non-gastric sites can be re-evaluated with clinical examination, laboratory work-up and imaging/biopsy of residual lesions if indicated every 3 months for the first 2 years, and every 6 months thereafter

Gastric MZL

- Sequential evaluation of gastric biopsies remains an essential follow-up procedure for gastric MZL, particularly in patients with persistent *Helicobacter pylori* infection

SMZL

- Specific criteria for response assessment are recommended for SMZL and achievement of CR is defined by normal spleen size, normal blood counts, negative flow cytometry on blood and negative IHC on bone marrow biopsy

B2M, β 2 microglobulin; ChT, chemotherapy; CR, complete remission; EMZL, extranodal marginal zone B-cell lymphoma; HBV, hepatitis B virus; HCV, hepatitis C virus; HIV, human immunodeficiency virus; HPLL, prognostic model based on haemoglobin concentration, platelet count, LDH level and extrahilar lymphadenopathy; IgD, immunoglobulin D; IHC, immunohistochemistry; ISRT, involved-site radiotherapy; LDH, lactate dehydrogenase; MALT-IPI, mucosa-associated lymphoid tissue-International Prognostic Index; MZL, marginal zone B-cell lymphoma; NMZL, nodal splenic marginal zone B-cell lymphoma; R, rituximab; R-CHOP, rituximab/cyclophosphamide/doxorubicin/vincristine/prednisone; R-CVP, rituximab/cyclophosphamide/vincristine/prednisone; RT, radiotherapy; SMZL, splenic marginal zone B-cell lymphoma.

risk of other non-Hodgkin lymphomas may be increased as well.⁸²

SMZL

In view of the particular clinical presentation of SMZL, specific criteria for response assessment are recommended (Table 5). In particular, achievement of CR is defined by normal spleen size, normal blood counts, negative flow cytometry on blood and negative IHC on bone marrow biopsy.^{9,22}

PERSONALISED MEDICINE

Risk stratification using the specific prognostic indices for EMZL²⁵ and SMZL^{26,28} may help the discussion of treatment options with patients, but these prognostic scores are not validated as tools to decide whether and which treatment is indicated.

In gastric MZL, the absence of *H. pylori*, the deep invasion of the gastric wall (beyond the submucosa), the involvement of regional lymph nodes, the presence of chromosomal translocations that result in deregulation of *MALT1* or *BCL10* and other genetic features (such as overexpression of miR-142-5p and miR-155) may be associated with a reduced probability of

lymphoma regression after antibiotics.^{5,30,31,43,83} As discussed in the 'Diagnosis and pathology/molecular biology' section, detection of *t(11;18)* may also help to identify patients less likely to respond to alkylating agents alone. Nevertheless, in this disease, more research is needed to identify and validate molecular markers which might lead to more precise targeted therapies. In SMZL, several molecular features (Ig mutational status, *NOTCH2* and *KLF2* mutations, *TP53* abnormalities, and aberrant promoter methylation) have been reported as potentially useful biomarkers, which might be integrated in the clinical indices for a better risk stratification.²²

METHODOLOGY

These Clinical Practice Guidelines were developed in accordance with the ESMO standard operating procedures for Clinical Practice Guidelines development, <http://www.esmo.org/Guidelines/ESMO-Guidelines-Methodology>. The relevant literature has been selected by the expert authors. A summary of recommendations is shown in Table 6. Levels of evidence and grades of recommendation have been applied using the system shown in Table 7. Statements without grading were considered justified standard clinical practice by the experts and the ESMO Faculty. This manuscript has been subjected to an anonymous peer review process.

Table 7. Level of evidence and grades of recommendation (adapted from the Infectious Diseases Society of America–United States Public Health Service Grading System^a)

Levels of evidence

- I Evidence from at least one large randomised, controlled trial of good methodological quality (low potential for bias) or meta-analyses of well-conducted randomised trials without heterogeneity
- II Small randomised trials or large randomised trials with a suspicion of bias (lower methodological quality) or meta-analyses of such trials or of trials with demonstrated heterogeneity
- III Prospective cohort studies
- IV Retrospective cohort studies or case–control studies
- V Studies without control group, case reports, expert opinions

Grades of recommendation

- A Strong evidence for efficacy with a substantial clinical benefit, strongly recommended
- B Strong or moderate evidence for efficacy but with a limited clinical benefit, generally recommended
- C Insufficient evidence for efficacy or benefit does not outweigh the risk or the disadvantages (adverse events, costs, etc.), optional
- D Moderate evidence against efficacy or for adverse outcome, generally not recommended
- E Strong evidence against efficacy or for adverse outcome, never recommended

^a By permission of the Infectious Diseases Society of America.⁸⁴

ACKNOWLEDGEMENTS

The ESMO Guidelines Committee would like to thank the ESMO Faculty and other experts who provided critical reviews of these ESMO Clinical Practice Guidelines.

FUNDING

No external funding has been received for the preparation of these guidelines. Production costs have been covered by ESMO from central funds.

DISCLOSURE

EZ has received research support from Roche, Janssen and Celgene; LA has reported consultancy or advisory role for Roche, Bayer, Celgene, Sandoz and Gilead Sciences, has received research funding from Gilead Sciences and travel expenses from Roche, Celgene, Gilead Sciences and EUSA Pharma and is a member of the speaker's bureau for Celgene; CB has received research support from Roche, Bayer, Amgen and Janssen; PWJ has received research support from Epizyme and Janssen and consultancy for Boehringer Ingelheim, Bristol-Myers Squibb, Pfizer, Celgene, Carrick, Karus, Genmab and Incyte; MR has received support from Celgene, Novartis, Ipsen and Roche; UR is a member of the speaker's bureau of AstraZeneca, Merck, Sharp and Dohme and Bayer; AS is a member of the speaker's bureau of Janssen, Roche and Mundipharma; KS has reported consultancy and advisory board for Janssen and Gilead Sciences and has received institutional research support from Janssen, Gilead Sciences and AbbVie; CT has reported consultancy or advisory role for Janssen, Roche, Bayer and Celgene, has received research funding from Roche and Janssen and travel expenses from Sanofi and Roche and is a member of the speaker's bureau for Collectis; AW has received service fees from Celgene and

Bristol-Myers Squibb and travel expenses from Pfizer; ML is a member of the speaker's bureau of Celgene, Janssen-Cilag, Roche, Bayer, Amgen and Mundipharma; MP has declared no conflicts of interest.

REFERENCES

1. Campo E, Pileri SA, Jaffe ES, et al. Nodal marginal zone B-cell lymphoma. In: Swerdlow SH, Campo E, Harris NL, et al., eds. *WHO Classification of Tumours of Haematopoietic and Lymphoid Tissues*. Revised 4th ed. Lyon: IARC; 2017:263–265.
2. Piris MA, Isaacson PI, Swerdlow SH, et al. Splenic marginal zone lymphoma. In: Swerdlow SH, Campo E, Harris NL, et al., eds. *WHO Classification of Tumours of Haematopoietic and Lymphoid Tissues*. Revised 4th ed. Lyon: IARC Press; 2017:223–225.
3. Cook JR, Isaacson PG, Chott A, et al. Extranodal marginal zone B-cell lymphoma of mucosa-associated lymphoid tissue (MALT lymphoma). In: Swerdlow SH, Campo E, Harris NL, et al., eds. *WHO Classification of Tumours of Haematopoietic and Lymphoid Tissues*. Revised 4th ed. Lyon: IARC Press; 2017:259–262.
4. Xochelli A, Kalpadakis C, Gardiner A, et al. Clonal B-cell lymphocytosis exhibiting immunophenotypic features consistent with a marginal-zone origin: is this a distinct entity? *Blood*. 2014;123:1199–1206.
5. Zucca E, Bertoni F. The spectrum of MALT lymphoma at different sites: biological and therapeutic relevance. *Blood*. 2016;127:2082–2092.
6. Dreyling M, Thieblemont C, Gallamini A, et al. ESMO Consensus conferences: guidelines on malignant lymphoma. Part 2: marginal zone lymphoma, mantle cell lymphoma, peripheral T-cell lymphoma. *Ann Oncol*. 2013;24:857–877.
7. Ruskone-Fourmesttraux A, Fischbach W, Aleman BM, et al. EGILS consensus report. Gastric extranodal marginal zone B-cell lymphoma of MALT. *Gut*. 2011;60:747–758.
8. Franco V, Florena AM, Iannitto E. Splenic marginal zone lymphoma. *Blood*. 2003;101:2464–2472.
9. Matutes E, Oscier D, Montalban C, et al. Splenic marginal zone lymphoma proposals for a revision of diagnostic, staging and therapeutic criteria. *Leukemia*. 2008;22:487–495.
10. Ponzoni M, Kanellis G, Poulou E, et al. Bone marrow histopathology in the diagnostic evaluation of splenic marginal-zone and splenic diffuse red pulp small B-cell lymphoma: a reliable substitute for spleen histopathology? *Am J Surg Pathol*. 2012;36:1609–1618.
11. Swerdlow SH, Campo E, Pileri SA, et al. The 2016 revision of the World Health Organization classification of lymphoid neoplasms. *Blood*. 2016;127:2375–2390.
12. Swerdlow SH, Kuzu I, Dogan A, et al. The many faces of small B cell lymphomas with plasmacytic differentiation and the contribution of MYD88 testing. *Virchows Arch*. 2016;468:259–275.
13. Raderer M, Kiesewetter B, Ferreri AJ. Clinicopathologic characteristics and treatment of marginal zone lymphoma of mucosa-associated lymphoid tissue (MALT lymphoma). *CA Cancer J Clin*. 2016;66:153–171.
14. Zucca E, Conconi A, Pedrinis E, et al. Nongastric marginal zone B-cell lymphoma of mucosa-associated lymphoid tissue. *Blood*. 2003;101:2489–2495.
15. Ruskone-Fourmesttraux A, Dragosics B, Morgner A, et al. Paris staging system for primary gastrointestinal lymphomas. *Gut*. 2003;52:912–913.
16. Mazloom A, Rodriguez A, Ha CS, et al. Incidence of gastric involvement in patients with nongastrointestinal extranodal marginal zone lymphoma. *Cancer*. 2011;117:2461–2466.
17. Ogusa E, Tomita N, Ishii Y, et al. Clinical manifestations of primary pulmonary extranodal marginal zone lymphoma of mucosa-associated lymphoid tissue in Japanese population. *Hematol Oncol*. 2013;31:18–21.
18. Thieblemont C, Felman P, Callet-Bauchu E, et al. Splenic marginal-zone lymphoma: a distinct clinical and pathological entity. *Lancet Oncol*. 2003;4:95–103.

19. Thieblemont C, Felman P, Berger F, et al. Treatment of splenic marginal zone B-cell lymphoma: an analysis of 81 patients. *Clin Lymphoma*. 2002;3:41–47.
20. Thieblemont C, Davi F, Noguera ME, et al. Splenic marginal zone lymphoma: current knowledge and future directions. *Oncology (Williston Park)*. 2012;26:194–202.
21. Traverse-Glehen A, Bertoni F, Thieblemont C, et al. Nodal marginal zone B-cell lymphoma: a diagnostic and therapeutic dilemma. *Oncology (Williston Park)*. 2012;26:92–99, 103–104.
22. Arcaini L, Rossi D, Paulli M. Splenic marginal zone lymphoma: from genetics to management. *Blood*. 2016;127:2072–2081.
23. Berger F, Felman P, Thieblemont C, et al. Non-MALT marginal zone B-cell lymphomas: a description of clinical presentation and outcome in 124 patients. *Blood*. 2000;95:1950–1956.
24. Arcaini L, Paulli M, Burcheri S, et al. Primary nodal marginal zone B-cell lymphoma: clinical features and prognostic assessment of a rare disease. *Br J Haematol*. 2007;136:301–304.
25. Thieblemont C, Cascione L, Conconi A, et al. A MALT lymphoma prognostic index. *Blood*. 2017;130:1409–1417.
26. Arcaini L, Lazzarino M, Colombo N, et al. Splenic marginal zone lymphoma: a prognostic model for clinical use. *Blood*. 2006;107:4643–4649.
27. Montalban C, Abraira V, Arcaini L, et al. Risk stratification for splenic marginal zone lymphoma based on haemoglobin concentration, platelet count, high lactate dehydrogenase level and extrahilar lymphadenopathy: development and validation on 593 cases. *Br J Haematol*. 2012;159:164–171.
28. Montalban C, Abraira V, Arcaini L, et al. Simplification of risk stratification for splenic marginal zone lymphoma: a point-based score for practical use. *Leuk Lymphoma*. 2014;55:929–931.
29. Kalpadakis C, Pangalis GA, Angelopoulou MK, et al. Validation of the simplified prognostic score for splenic marginal zone lymphoma of the Splenic Marginal Zone Lymphoma Working Group. *Leuk Lymphoma*. 2014;55:2640–2642.
30. Thieblemont C, Zucca E. Clinical aspects and therapy of gastrointestinal MALT lymphoma. *Best Pract Res Clin Haematol*. 2017;30:109–117.
31. Bertoni F, Coiffier B, Salles G, et al. MALT lymphomas: pathogenesis can drive treatment. *Oncology (Williston Park)*. 2011;25:1134–1142, 1147.
32. Fuccio L, Laterza L, Zagari RM, et al. Treatment of *Helicobacter pylori* infection. *BMJ*. 2008;337:a1454.
33. Zullo A, Hassan C, Cristofari F, et al. Effects of *Helicobacter pylori* eradication on early stage gastric mucosa-associated lymphoid tissue lymphoma. *Clin Gastroenterol Hepatol*. 2010;8:105–110.
34. Zullo A, Hassan C, Ridola L, et al. Eradication therapy in *Helicobacter pylori*-negative, gastric low-grade mucosa-associated lymphoid tissue lymphoma patients: a systematic review. *J Clin Gastroenterol*. 2013;47:824–827.
35. Kiesewetter B, Raderer M. Antibiotic therapy in nongastrointestinal MALT lymphoma: a review of the literature. *Blood*. 2013;122:1350–1357.
36. Arcaini L, Vallisa D, Rattotti S, et al. Antiviral treatment in patients with indolent B-cell lymphomas associated with HCV infection: a study of the Fondazione Italiana Linfomi. *Ann Oncol*. 2014;25:1404–1410.
37. Wirth A, Gospodarowicz M, Aleman BM, et al. Long-term outcome for gastric marginal zone lymphoma treated with radiotherapy: a retrospective, multi-centre, International Extranodal Lymphoma Study Group study. *Ann Oncol*. 2013;24:1344–1351.
38. Goda JS, Gospodarowicz M, Pintilie M, et al. Long-term outcome in localized extranodal mucosa-associated lymphoid tissue lymphomas treated with radiotherapy. *Cancer*. 2010;116:3815–3824.
39. Lowry L, Smith P, Qian W, et al. Reduced dose radiotherapy for local control in non-Hodgkin lymphoma: a randomised phase III trial. *Radiother Oncol*. 2011;100:86–92.
40. Yahalom J, Illidge T, Specht L, et al. Modern radiation therapy for extranodal lymphomas: field and dose guidelines from the International Lymphoma Radiation Oncology Group. *Int J Radiat Oncol Biol Phys*. 2015;92:11–31.
41. Hoskin PJ, Kirkwood AA, Popova B, et al. 4 Gy versus 24 Gy radiotherapy for patients with indolent lymphoma (FORT): a randomised phase 3 non-inferiority trial. *Lancet Oncol*. 2014;15:457–463.
42. Fasola CE, Jones JC, Huang DD, et al. Low-dose radiation therapy (2 Gy x 2) in the treatment of orbital lymphoma. *Int J Radiat Oncol Biol Phys*. 2013;86:930–935.
43. Thieblemont C. Clinical presentation and management of marginal zone lymphomas. *Hematology (Am Soc Hematol Educ Program)*. 2005:307–313.
44. Hammel P, Haioun C, Chaumette MT, et al. Efficacy of single-agent chemotherapy in low-grade B-cell mucosa-associated lymphoid tissue lymphoma with prominent gastric expression. *J Clin Oncol*. 1995;13:2524–2529.
45. Jager G, Neumeister P, Brezinschek R, et al. Treatment of extranodal marginal zone b-cell lymphoma of mucosa-associated lymphoid tissue type with cladribine: a phase II study. *J Clin Oncol*. 2002;20:3872–3877.
46. Zucca E, Conconi A, Martinelli G, et al. Final results of the IELSG-19 randomized trial of mucosa-associated lymphoid tissue lymphoma: improved event-free and progression-free survival with rituximab plus chlorambucil versus either chlorambucil or rituximab monotherapy. *J Clin Oncol*. 2017;35:1905–1912.
47. Conconi A, Martinelli G, Thieblemont C, et al. Clinical activity of rituximab in extranodal marginal zone B-cell lymphoma of MALT type. *Blood*. 2003;102:2741–2745.
48. Martinelli G, Laszlo D, Conconi A, et al. Anti-CD20 monoclonal antibody (rituximab) in gastric extranodal marginal zone (MALT) non-Hodgkins lymphoma (NHL) patients: clinical and biological results (phase II study). *Blood*. 2003;102:410a.
49. Raderer M, Jager G, Brugger S, et al. Rituximab for treatment of advanced extranodal marginal zone B cell lymphoma of the mucosa-associated lymphoid tissue lymphoma. *Oncology*. 2003;65:306–310.
50. Salar A, Domingo-Domenech E, Panizo C, et al. First-line response-adapted treatment with the combination of bendamustine and rituximab in patients with mucosa-associated lymphoid tissue lymphoma (MALT2008-01): a multicentre, single-arm, phase 2 trial. *Lancet Haematol*. 2014;1:e104–e111.
51. Salar A, Domingo-Domenech E, Panizo C, et al. Long-term results of a phase II study of rituximab and bendamustine for mucosa-associated lymphoid tissue lymphoma. *Blood*. 2017;130:1772–1774.
52. Rummel MJ, Koenigsmann M, Chow KU, et al. Two years rituximab maintenance vs. observation after first line treatment with bendamustine plus rituximab (B-R) in patients with marginal zone lymphoma (MZL): Results of a prospective, randomized, multicenter phase 2 study (the Stil NHL7-2008 MAINTAIN trial). *J Clin Oncol*. 2018;36:7515.
53. Stathis A, Gregorini A, Gressin R, et al. IELSG-38: A phase II study of chlorambucil in combination with rituximab followed by maintenance therapy with subcutaneous rituximab in patients with extranodal marginal zone B-cell lymphoma of mucosa associated lymphoid tissue (MALT). *Blood*. 2017;130:1506.
54. Hancock BW, Qian W, Linch D, et al. Chlorambucil versus observation after anti-*Helicobacter* therapy in gastric MALT lymphomas: results of the international randomised LY03 trial. *Br J Haematol*. 2009;144:367–375.
55. Kiesewetter B, Willenbacher E, Willenbacher W, et al. A phase 2 study of rituximab plus lenalidomide for mucosa-associated lymphoid tissue lymphoma. *Blood*. 2017;129:383–385.
56. Salar A, Domingo-Domenech E, Estany C, et al. Combination therapy with rituximab and intravenous or oral fludarabine in the first-line, systemic treatment of patients with extranodal marginal zone B-cell lymphoma of the mucosa-associated lymphoid tissue type. *Cancer*. 2009;115:5210–5217.
57. Brown JR, Friedberg JW, Feng Y, et al. A phase 2 study of concurrent fludarabine and rituximab for the treatment of marginal zone lymphomas. *Br J Haematol*. 2009;145:741–748.
58. Tilly H, Gomes da Silva M, Vitolo U, et al. Diffuse large B-cell lymphoma (DLBCL): ESMO Clinical Practice Guidelines for diagnosis, treatment and follow-up. *Ann Oncol*. 2015;26(Suppl 5):v116–v125.
59. Koch P, Probst A, Berdel WE, et al. Treatment results in localized primary gastric lymphoma: data of patients registered within the German multicenter study (GIT NHL 02/96). *J Clin Oncol*. 2005;23:7050–7059.
60. Zucca E, Stathis A, Bertoni F. The management of nongastric MALT lymphomas. *Oncology (Williston Park)*. 2014;28:86–93.

61. Arcaini L, Paulli M, Boveri E, et al. Splenic and nodal marginal zone lymphomas are indolent disorders at high hepatitis C virus seroprevalence with distinct presenting features but similar morphologic and phenotypic profiles. *Cancer*. 2004;100:107–115.
62. Chacon JI, Mollejo M, Munoz E, et al. Splenic marginal zone lymphoma: clinical characteristics and prognostic factors in a series of 60 patients. *Blood*. 2002;100:1648–1654.
63. Kalpadakis C, Pangalis GA, Angelopoulou MK, et al. Treatment of splenic marginal zone lymphoma with rituximab monotherapy: progress report and comparison with splenectomy. *Oncologist*. 2013;18:190–197.
64. Lefrere F, Hermine O, Belanger C, et al. Fludarabine: an effective treatment in patients with splenic lymphoma with villous lymphocytes. *Leukemia*. 2000;14:573–575.
65. Cervetti G, Galimberti S, Pelosini M, et al. Significant efficacy of 2-chlorodeoxyadenosine ± rituximab in the treatment of splenic marginal zone lymphoma (SMZL): extended follow-up. *Ann Oncol*. 2013;24:2434–2438.
66. Tsimberidou AM, Catovsky D, Schlette E, et al. Outcomes in patients with splenic marginal zone lymphoma and marginal zone lymphoma treated with rituximab with or without chemotherapy or chemotherapy alone. *Cancer*. 2006;107:125–135.
67. Kalpadakis C, Pangalis GA, Dimopoulou MN, et al. Rituximab monotherapy is highly effective in splenic marginal zone lymphoma. *Hematol Oncol*. 2007;25:127–131.
68. Bennett M, Sharma K, Yegena S, et al. Rituximab monotherapy for splenic marginal zone lymphoma. *Haematologica*. 2005;90:856–858.
69. Iannitto E, Bellei M, Amorim S, et al. Efficacy of bendamustine and rituximab in splenic marginal zone lymphoma: results from the phase II BRISMA/IELSG36 study. *Br J Haematol*. 2018;183:755–765.
70. Kalpadakis C, Pangalis GA, Sachanas S, et al. Rituximab monotherapy in splenic marginal zone lymphoma: prolonged responses and potential benefit from maintenance. *Blood*. 2018;132:666–670.
71. Kalpadakis C, Pangalis GA, Angelopoulou MK, et al. Treatment of splenic marginal zone lymphoma. *Best Pract Res Clin Haematol*. 2017;30:139–148.
72. Kalpadakis C, Pangalis GA, Angelopoulou MK, et al. Should rituximab replace splenectomy in the management of splenic marginal zone lymphoma? *Best Pract Res Clin Haematol*. 2018;31:65–72.
73. Marcus R, Davies A, Ando K, et al. Obinutuzumab for the first-line treatment of follicular lymphoma. *N Engl J Med*. 2017;377:1331–1344.
74. Herold M, Hoster E, Janssens A, et al. Immunochemotherapy with obinutuzumab or rituximab in a subset of patients in the randomised GALLIUM trial with previously untreated marginal zone lymphoma (MZL). *Hematol Oncol*. 2017;35:146–147.
75. Noy A, de Vos S, Thieblemont C, et al. Targeting Bruton tyrosine kinase with ibrutinib in relapsed/refractory marginal zone lymphoma. *Blood*. 2017;129:2224–2232.
76. Dreyling M, Santoro A, Mollica L, et al. Phosphatidylinositol 3-kinase inhibition by copanlisib in relapsed or refractory indolent lymphoma. *J Clin Oncol*. 2017;35:3898–3905.
77. Copie-Bergman C, Wotherspoon AC, Capella C, et al. Gela histological scoring system for post-treatment biopsies of patients with gastric MALT lymphoma is feasible and reliable in routine practice. *Br J Haematol*. 2013;160:47–52.
78. Nakamura S, Sugiyama T, Matsumoto T, et al. Long-term clinical outcome of gastric MALT lymphoma after eradication of *Helicobacter pylori*: a multicentre cohort follow-up study of 420 patients in Japan. *Gut*. 2012;61:507–513.
79. Stathis A, Chini C, Bertoni F, et al. Long-term outcome following *Helicobacter pylori* eradication in a retrospective study of 105 patients with localized gastric marginal zone B-cell lymphoma of MALT type. *Ann Oncol*. 2009;20:1086–1093.
80. Wundisch T, Thiede C, Morgner A, et al. Long-term follow-up of gastric MALT lymphoma after *Helicobacter pylori* eradication. *J Clin Oncol*. 2005;23:8018–8024.
81. Capelle LG, de Vries AC, Looman CW, et al. Gastric MALT lymphoma: epidemiology and high adenocarcinoma risk in a nation-wide study. *Eur J Cancer*. 2008;44:2470–2476.
82. Wundisch T, Dieckhoff P, Greene B, et al. Second cancers and residual disease in patients treated for gastric mucosa-associated lymphoid tissue lymphoma by *Helicobacter pylori* eradication and followed for 10 years. *Gastroenterology*. 2012;143:936–942. quiz e913–934.
83. Saito Y, Suzuki H, Tsugawa H, et al. Overexpression of miR-142-5p and miR-155 in gastric mucosa-associated lymphoid tissue (MALT) lymphoma resistant to *Helicobacter pylori* eradication. *PLoS One*. 2012;7:e47396.
84. Dykewicz CA. Summary of the guidelines for preventing opportunistic infections among hematopoietic stem cell transplant recipients. *Clin Infect Dis*. 2001;33:139–144.

Update

Annals of Oncology

Volume 34, Issue 3, March 2023, Page 325

DOI: <https://doi.org/10.1016/j.annonc.2022.11.009>

CORRIGENDUM

Corrigendum to “Marginal zone lymphomas: ESMO Clinical Practice Guidelines for diagnosis, treatment and follow-up”



[Annals of Oncology 31 (2020) 17–29]

E. Zucca^{1,2,3}, L. Arcaini^{4,5}, C. Buske⁶, P. W. Johnson⁷, M. Ponzoni⁸, M. Raderer⁹, U. Ricardi¹⁰, A. Salar¹¹, K. Stamatopoulos¹², C. Thieblemont¹³, A. Wotherspoon¹⁴ & M. Ladetto¹⁵, on behalf of the ESMO Guidelines Committee*

¹Division of Medical Oncology, Oncology Institute of Southern Switzerland, Bellinzona; ²Department of Medical Oncology, Inselspital, Bern University Hospital, University of Bern, Bern; ³Institute of Oncology Research, Bellinzona, Switzerland; ⁴Division of Hematology, Fondazione IRCCS Policlinico San Matteo, Pavia; ⁵Department of Molecular Medicine, University of Pavia, Pavia, Italy; ⁶Comprehensive Cancer Centre, University Hospital of Ulm, Ulm, Germany; ⁷Cancer Research UK Centre, Southampton General Hospital, Southampton, UK; ⁸Vita-Salute San Raffaele University and Pathology Unit, San Raffaele Scientific Institute, Milan, Italy; ⁹Internal Medicine I, Division of Oncology, Medical University Vienna, Vienna, Austria; ¹⁰Department of Oncology, University of Turin, Turin, Italy; ¹¹Department of Hematology, Hospital del Mar, Barcelona, Barcelona, Spain; ¹²Institute of Applied Biosciences, CERTH, the Centre for Research and Technology Hellas, Thessaloniki, Greece; ¹³Department of Hematology, APHP-Saint-Louis Hospital, University Paris-Diderot, Paris, France; ¹⁴Department of Histopathology, The Royal Marsden Hospital, London, UK; ¹⁵Division of Hematology, Azienda Ospedaliera SS. Antonio e Biagio e Cesare Arrigo, Alessandria, Italy

The authors regret that in the section EMZL the sentence “In addition to routine histology and IHC, fluorescent in situ hybridisation (FISH) studies for detection of t(11;18)(p21;p21) may be useful for identifying gastric MZL patients who are unlikely to respond to antibiotic therapy [III, B].5” should read “In addition to routine histology and IHC, fluorescent in situ hybridisation (FISH) studies for detection of t(11;18)(q21;q21) may be useful for identifying gastric MZL patients who are unlikely to respond to antibiotic therapy [III, B].5”

The authors would like to apologise for any inconvenience caused.

DOI of original article: <https://doi.org/10.1016/j.annonc.2019.10.010>

*Correspondence to: ESMO Guidelines Committee, ESMO Head Office, Via Ginevra 4, CH-6900 Lugano, Switzerland
E-mail: clinicalguidelines@esmo.org (ESMO Guidelines Committee).

0923-7534/© 2022 European Society for Medical Oncology. Published by Elsevier Ltd. All rights reserved.