Magnetic resonance imaging in sarcoglycanopathies: a large international cohort study

Giorgio Tasca, MD, PhD [1, *], Mauro Monforte, MD [1], Jordi Díaz-Manera, MD [2,3], Giacomo Brisca, MD [4], Claudio Semplicini, MD [5], Adele D'Amico, MD [6], Fabiana Fattori, PhD [6], Anna Pichiecchio, MD [7], Angela Berardinelli, MD [8], Lorenzo Maggi, MD [9], Elio Maccagnano, MD [10,11], Nicoline Løkken, MD [12], Chiara Marini-Bettolo, MD [13], Francina Munell, MD [14], Angel Sanchez, MD [15], Nahla Alshaikh, MD [16], Nicol C. Voermans, MD [17], Jahannaz Dastgir, MD [18], Dmitry Vlodavets, MD [19], Jana Haberlova, MD [20], Gianmichele Magnano, MD [21], Maggie C. Walter, MD [22], Susana Quijano-Roy, MD [23], Robert-Yves Carlier, MD [24], Baziel Van Engelen, MD [17], John Vissing, MD [12], Volker Straub, MD [13], Carsten G. Bönnemann, MD [18], Eugenio Mercuri, MD [25], Francesco Muntoni, MD [16], Elena Pegoraro, MD [5], Enrico Bertini, MD [6], Bjarne Udd, MD [26,27,28], Enzo Ricci, MD [1, #], Claudio Bruno, MD [4, #].

[1] Istituto di Neurologia, Università Cattolica del Sacro Cuore, Fondazione Policlinico Universitario "A. Gemelli", Rome, Italy.

[2] Neuromuscular disorders Unit. Neurology department. Universitat Autonoma de Barcelona. Hospital de la Santa Creu I Sant Pau. Barcelona, Spain.

[3] Centro de Investigación Biomédica en Red en Enfermedades Raras, Barcelona, Spain (CIBERER).

[4] Center of Translational Myology and Neurodegenerative Diseases, Istituto Giannina Gaslini, Genova, Italy.

[5] Department of Neuroscience, University of Padova, Padova, Italy.

[6] Unit of Neuromuscular and Neurodegenerative Diseases, Department of Neurosciences, Bambino Gesù Children's Hospital, Rome, Italy.

[7]Neuroradiology Department, National Neurological Institute C.Mondino, Pavia, Italy

[8] Child Neurology and Psychiatry Unit, National Neurological Institute C. Mondino, Pavia, Italy.

[9]U.O. Neuroimmunologia e Malattie Neuromuscolari, Fondazione IRCCS Istituto Neurologico Carlo Besta, Milan, Italy.

[10] U.O. Neuroradiologia, Fondazione IRCCS Istituto Neurologico Carlo Besta, Milan, Italy.

[11] Servizio di Diagnostica per Immagini, Centro Diagnostico Italiano, Milan, Italy.

[12] Copenhagen Neuromuscular Center, Rigshospitalet, University of Copenhagen, Denmark.

[13] The John Walton Muscular Dystrophy Research Centre, Institute of Genetic Medicine, Newcastle University, Newcastle upon Tyne, United Kingdom.

[14] Pediatric neurology, Hospital Universitari Vall d'Hebron, Barcelona, Spain.

[15] Radiology, Hospital Universitari Vall d'Hebron, Barcelona, Spain.

[16] Dubowitz Neuromuscular Centre, UCL Great Ormond Street Institute of Child Health, London, United Kingdom.

[17] Dept. of Neurology, Donders Institute for Brain, Cognition and Behaviour, Radboud University Medical Center, Nijmegen, The Netherlands.

[18] National Institute of Neurological Disorders and Stroke, NIH, Bethesda, Maryland, USA.

[19] Russian Children Neuromuscular Center, Veltischev Scientific Research Clinical Institute of Pediatrics, Pirogov Russian National Research Medical University, Moscow, Russia.

[20] Department of Paediatric Neurology, 2nd Faculty of Medicine, Charles University in Prague and University Hospital Motol, Prague, Czech Republic.

[21] Radiology Unit, Istituto Giannina Gaslini, Genova, Italy.

[22] Friedrich-Baur-Institute, Dept. of Neurology, Ludwig-Maximilians-University of Munich, Germany.

[23] Assistance Publique des Hôpitaux de Paris (AP-HP), Unité Neuromusculaire, Service de Pédiatrie, Hôpital Raymond Poincaré, Hôpitaux Universitaires Paris-Ile-de-France Ouest, Garches, U1179 INSERM, Université de Versailles (UVSQ), Centre de Référence Neuromusculaire GNMH, FILNEMUS, France.

[24] Department of Radiology, Neurolocomotor Division, Raymond Poincaré Hospital, University Hospitals Paris-Ile-de-France West, Public Hospital Network of Paris, Garches, France.

[25] Neuropsichiatria Infantile, Università Cattolica del Sacro Cuore, Rome, Italy.

[26] Neuromuscular Research Center, Tampere University and University Hospital, Neurology, Tampere, Finland.

[27] Folkhälsan Institute of Genetics and the Department of Medical Genetics, University of Helsinki, Helsinki, Finland.

[28] Vaasa Central Hospital, Department of Neurology, Vaasa, Finland.

[#] Shared senior authorship

* **Corresponding author:** G. Tasca, Istituto di Neurologia, Università Cattolica del Sacro Cuore, Fondazione Policlinico Universitario "A. Gemelli", Largo A. Gemelli, 8, 00168 Rome, Italy. Phone: +39-06-30155869. Fax: +39-06-35501909. E-mail: giorgiotasca81@gmail.com.

Total word count: 2409

Abstract word count: 235

References: 27

Received 24 June 2017

Revised 22 August 2017

Accepted 23 August 2017

ABSTRACT

OBJECTIVES: To characterize the pattern and spectrum of involvement on muscle magnetic resonance imaging (MRI) in a large cohort of patients with sarcoglycanopathies, which are Limb-Girdle Muscular Dystrophies (LGMD2C-2F) caused by mutations in one of the four genes coding for muscle sarcoglycans.

METHODS: Lower limb MRI scans of LGMD2C-2F patients, ranging from severe childhood variants to milder adult onset forms, were collected in 17 neuromuscular referral centers in Europe and USA. Muscle involvement was evaluated semiquantitatively on T1-weighted images according to a visual score, and the global pattern was assessed as well.

RESULTS: Scans from 69 patients were examined (38 LGMD2D, 18 LGMD2C, 12 LGMD2E and 1 LGMD2F). A common pattern of involvement was found in all the analyzed scans irrespective of the mutated gene. The most and earliest affected muscles were the thigh adductors, glutei and posterior thigh groups, while lower leg muscles were relatively spared even in advanced disease. A proximo-distal gradient of involvement of vasti muscles was a consistent finding in these patients, including the most severe ones.

CONCLUSIONS: Muscle involvement on MRI is consistent in LGMD2C-F patients and can be helpful in distinguishing sarcoglycanopathies from other LGMDs or dystrophinopathies, which represent the most common differential diagnoses. Our data provide evidence about selective susceptibility or resistance to degeneration of specific muscles when one of the sarcoglycans is deficient as well as preliminary information about progressive involvement of the different muscles over time.

INTRODUCTION

Limb-girdle muscular dystrophies (LGMD) 2C, 2D, 2E and 2F are caused by mutations in the four genes coding for gamma, alpha, beta and delta sarcoglycans, and are therefore also referred to as sarcoglycanopathies. Sarcoglycans are a complex of glycopeptides associated with dystrophin and other proteins at the level of the sarcolemma, to form the so-called dystrophin-associated glycoprotein complex (DAGC) [1].

As for all the LGMDs, the correct molecular diagnosis is of great importance for adequate care management, planning the genetic counselling, scheduling the correct follow-up and allowing enrollment in ongoing and future gene therapy trials [2]. Sarcoglycanopathies can have a pediatric or adult age of onset and show overlapping features with other muscular dystrophies, e.g. dystrophinopathies or alpha-dystroglycanopathies, being characterized by high CK level, a similar distribution of weakness, calf muscle hypertrophy and not infrequently cardiomyopathy [1,3]. The genetic diagnosis is addressed by muscle pathology that discloses an absence or reduction of one or more of the sarcoglycans. However, pathological diagnosis can occasionally be challenging since a defect in a protein of the DAGC can cause a secondary reduction of all the proteins of the complex, thus making it hard to identify the primary defect [4]. It is also known that a number of patients with partial sarcoglycan deficiency on muscle biopsy have no definite molecular genetic diagnosis [5,6].

Magnetic resonance imaging (MRI) has been increasingly exploited to identify muscle involvement and monitor disease progression in many inherited [7,8] and acquired myopathies [9]. However, only few sarcoglycanopathy patients have been described with muscle imaging so far [10,11], mostly LGMD2D [7,12,13] or LGMD2C [14]. A pattern of involvement in sarcoglycanopathies, proposed in a more recent study by ten Dam et al.

as derived from a literature search (i.e., predominant involvement of anterior thigh compartment, especially vastus intermedius; predominant involvement of soleus and peroneal group at the lower leg level; frequent hypertrophy of sartorius and gracilis) [15], was proven to be quite specific but insensitive (22%) to distinguish 11 CT scans of sarcoglycanopathies from other dystrophies, and the authors advised assessments of larger groups.

The aim of our study is to describe the pattern and spectrum of muscle involvement in a multicentric cohort of sarcoglycanopathies assessed by MRI. This is expected to improve the distinction of sarcoglycanopathies from other muscular dystrophies and possibly from each other. We also intend to provide cross-sectional, baseline data on muscle imaging that are currently missing in these diseases.

PATIENTS AND METHODS

Patients

Patients with a diagnosis of LGMD2C-2F followed in the 17 participating neuromuscular centers in Europe (Italy, Finland, UK, Spain, France, Germany, Denmark, the Netherlands, Czech Republic, Russia) and USA, in the framework of the MYO-MRI COST Action (www.myo-mri.eu), were enrolled if they had already had or were available for a new lower limb MRI scan.

MRI scans and evaluation

MRI studies were performed using different 1.5T scanners according to standard protocols [16]. T1-weighted sequences were acquired covering the body length from proximal lumbar spine to the ankles for the majority of the scans. Few scans were acquired only from the femur heads to the ankles.

All the scans were independently evaluated by two observers, neurologists with experience in muscle imaging (GT and MM), blinded to the molecular diagnosis, using a five-point scale estimating the extent of fatty replacement of single muscles as in previous studies [16,17], with scores ranging from 0 (normal appearance) to 4 (complete fatty replacement). In case of discordance between the observers, agreement was reached by consultation. A cumulative score per patient (T1-MRI score), as well as a median score per muscle were calculated. If the pelvic region was not covered, the scores of the muscles not entirely visualized were considered as missing values. Hierarchical analysis was performed using R software version 3.1.3 (The R Foundation for Statistical Computing; http://www.r-project.org) as previously described [18]. The Gower's distance was used for the clustering of patients and muscles. Scans were also judged to assess the overall pattern of involvement.

This study was approved by the Ethics Committees of the involved Institutions. All involved subjects or their legal guardians gave their written informed consent.

RESULTS

Patients

Sixty-nine patients were enrolled in the study. Thirty-eight were LGMD2D, 18 were LGMD2C, 12 were LGMD2E and 1 was LGMD2F. The age at scan ranged between 4-59 years, and patients were almost equally distributed between pediatric (age ≤18 years: 36 patients) and adult age (age > 18 years: 33 patients). Thirty-four patients were males and 35 females. Sixty-six patients had a complete molecular diagnosis with two mutations in one of the sarcoglycan genes, while 3 had only one pathogenic mutation and a clear reduction of staining of one or more sarcoglycans on muscle biopsy. In these

3 patients deletions/duplications or deep intronic mutations on the other allele had not been ruled out.

Clinical severity ranged from asymptomatic or mildly affected to severe, wheelchair bound patients (both children and adults). A summary of clinical and genetic features is reported in Supplementary Table 1.

Muscle imaging

Six patients, 5 LGMD2D and one LGMD2C, had normal lower limb MRI at age 9-26 years. Five patients (age at scan 4-7 years, 2 LGMD2D, 2 LGMD2C, 1 LGMD2E) showed only minor changes and had a T1-MRI score < 8. In these mildly affected patients, initial abnormalities were mostly in the adductor magnus and glutei muscles. The overall involvement was symmetrical (side-to side differences of at least two points in the scores were found only in 4 couples of muscles out of 2448). The complete set of data is shown in Supplementary Table 2.

Pelvis

Gluteus minimus and medius, quadratus femoris, adductor minimus and brevis, obturator internus and pectineus were the most severely affected muscles (median score 4). Glutei and adductors were also among the most frequently affected muscles together with piriformis (score ≥1 in >82% of the patients). Recti abdominis were never more affected than obliqui, except in one patient. Gluteus maximus was more involved than gluteus minimus only in 5 patients. Iliopsoas (median score 1) and tensor fasciae latae (median score 2) were among the relatively spared muscles, at least in the mild or moderately affected patients (Fig. 1 and 2).

Thigh

Adductor magnus was the most frequently and severely affected muscle in these disorders (Fig. 2). With the exception of the mildest patients, all the others (56/69) had a complete or almost complete fatty replacement (score 3-4) of both adductor magnus muscles. The other most severely affected muscles were adductor longus, vastus intermedius, biceps femoris long head, and semimembranosus (median score 3). In the posterior thigh, semitendinosus was more affected than semimembranosus only in two patients. Among the vasti muscles, vastus intermedius was the most severely involved, followed by vastus medialis and lateralis (Fig. 2). Vastus lateralis showed areas of sparing in the distal part close to the knee even in the most affected patients (score 4 only in 3/138 muscles). Sartorius and gracilis were the most spared muscles of the thigh: 34 and 39/69 patients, respectively, had a complete bilateral sparing (Fig. 1).

Lower leg

Lower leg was completely or almost completely spared in the majority of patients. If affected, the anterior compartment was more involved than the posterior, tibialis anterior and extensor hallucis/digitorum longus being the most affected muscles. Tibialis posterior and flexor digitorum longus were typically completely spared even in advanced disease (score 0 of both muscles in 60 and 61/69 patients respectively) (Fig. 1).

Pattern recognition and "gestaltic" criteria

Consistent features emerged from the assessment of muscle scans for pattern recognition. In the anterior thigh, while vasti were frequently involved in the proximal part, a clearly less prominent involvement in the distal portion could be noticed in most

patients (Fig. 3). This proximo-distal gradient was more evident in the vastus lateralis and present also in the most severely affected patients. Another muscle often showing small and symmetrical areas of sparing, although in the medial part, was adductor longus (Fig. 3). These features were typically combined with no or only minor changes in the lower leg, and with a complete or relative sparing of tibialis posterior and flexor digitorum longus. Less consistently there was also a sparing of tensor fasciae latae compared with the other pelvic muscles, and a relative hypertrophy of either sartorius or gracilis. No major differences could be found between males and females (Figure 2B). A summary of these "gestaltic" criteria is provided in Table 1.

Differences between sarcoglycanopathies

No major differences among the sarcoglycanopathies could be found regarding the pattern of muscle involvement, in particular comparing LGMD2D and LGMD2C that were the most prevalent forms. This inspective finding was confirmed by the hierarchical analysis (Fig. 2B). The only LGMD2F patient studied was more severe, but the affected and relatively spared muscles were similar to the other groups (Figure 4). Three patients (IT1_11, ES1_5, and IT5_7) showed a mild phenotype and severity on MRI at older age, with a T1-MRI score of 73 at age 54, 65 at 47, and 18 at 55 respectively. Interestingly, all were LGMD2D and two had the same genotype (homozygous p.R284C mutation). Their pattern of involvement was consistent with the others.

DISCUSSION

To the best of our knowledge, in the present study we report the largest cohort of LGMD2C-2F patients studied by muscle imaging so far, covering most of the spectrum of age and severity ranging from asymptomatic to wheelchair bound patients.

Collectively, the sarcoglycanopathies are among the most common LGMDs worldwide [3], representing the third most common form in Italy [19], and definitely one of the most severe. LGMD2D is generally the most common, followed by LGMD2C, whilst LGMD2F is the rarest [3]. Our cohort mainly consisted of patients affected by LGMD2D and LGMD2C, which reflects the general prevalence of sarcoglycanopathies worldwide.

Although this is not a longitudinal study, the large cohort and broad clinical spectrum allow us to make some inferences also on disease progression. Adductor and glutei muscles seem to be the first affected in the disease course, followed by small pelvic and obturator muscles, biceps femoris long head, vastus intermedius, proximal vastus lateralis and medialis and other posterior thigh muscles (Fig. 2). Iliopsoas is typically relatively spared early in the disease. Lower leg is not significantly involved until loss of ambulation occurs (Fig. 2B), and it is always less affected than pelvis and thigh. Tibialis posterior and flexor digitorum longus are particularly resistant to pathology even in advanced disease.

Our findings are consistent with the previously reported minor involvement of the lower leg [10,11]. At variance with the pattern proposed by ten Dam [15], we found that the adductor compartment of the thigh is more involved than the anterior one. We also add the following features to the previous descriptions: the sparing of the medial part of adductor longus, which in our experience is a rather peculiar although not completely specific finding, and most importantly the relative sparing of the distal quadriceps, that, together with the sparing of the lower leg, collectively configure LGMD2C-2F as a

“typical” LGMD phenotype with an easily recognizable proximo-distal gradient of involvement.

The most important differential diagnoses include muscular dystrophies with hypertrophic phenotype, mainly dystrophinopathies (Becker muscular dystrophy or forms with an intermediate severity between Duchenne and Becker muscular dystrophies) and alpha-dystroglycanopathies, especially LGMD2I. The complete or relative lower leg sparing has not been described in any of these conditions, with the exception of the mildest Becker patients [20]. Moreover, in dystrophinopathies, LGMD2I, and *ISPD*-mutated patients the involvement is usually posterior more than anterior in the lower leg [13,20–22]. The sparing of the distal quadriceps also seems to be very specific for LGMD2C-2F and not reported elsewhere. In addition, one common feature of dystrophinopathies is that gluteus maximus is the most affected among the glutei [20,21], at variance with LGMD2C-2F. The pattern we describe is also different from the other autosomal recessive [23] or dominant muscular dystrophies [24,25], which are unlikely to display predominantly anterior and milder involvement at leg level compared to the thigh. Lower leg sparing may be a feature of late-onset Pompe disease [26], but at variance with sarcoglycanopathies iliopsoas is usually involved early and it is not common to find anterior leg involvement in patients with Pompe disease. Conversely, the pattern of involvement seems to be homogenous among the different sarcoglycan defects. This supports the idea of a common pathophysiology shared by these disorders: as sarcoglycans are tightly interacting proteins, their functions and target muscles in case of damage are likely similar. Although additional evidences coming from dedicated studies are needed to confirm these findings, it seems reasonable to speculate that, assuming the apparent absence of fatty replacement in calf muscles of the majority of sarcoglycanopathy patients especially at early stages, a major contribution to calf

hypertrophy in sarcoglycanopathies could be given by an increase in “real” muscle tissue rather than by fat deposition, similarly to what happens in Becker muscular dystrophy [27].

Our study has some limitations. First of all, despite the consortium involving 17 neuromuscular centers we were able to enroll only one LGMD2F patient, given the rarity of this disease. Further delta-sarcoglycanopathy patients studied with MRI are necessary to verify our findings. Another limitation is that quantitative measurements for intramuscular adipose tissue and T2 signal were not performed in our study. Collection of such data along with standard MRI sequences will be of particular importance in longitudinal, natural history studies.

In conclusion, MRI is a helpful tool to guide the differential diagnosis within muscular dystrophies with hypertrophic phenotype. It can be used to address genetic testing in the presence of a compatible phenotype and, in case of sarcoglycan reduction on biopsy, to support the decision to push forward the genetic screening, for example searching for deletions or intronic mutations, or instead to consider the sarcoglycan defect as secondary. In addition, results of muscle imaging may be helpful in the interpretation of variants of unknown clinical significance in the sarcoglycan genes. The selective sparing of some muscles can be an interesting clue to the understanding of the pathophysiology of these disorders. Imaging of other body segments is warranted to assess whether there are further selective patterns. Our study also provides a comprehensive overview of distribution and extent of muscle pathology in a large cohort of LGMD2D-2F patients. This information can be used for designing clinical trials and to set the stage for longitudinal and quantitative MRI studies, that are needed to reliably determine disease progression as well as to confirm the possible use of imaging as an outcome measure in these diseases.

ACKNOWLEDGEMENTS

This publication is supported by the European Cooperation in Science and Technology (COST). GT, MM, JDM, AP, FM, AS, JH, MCW, SQR, RYC, JV, VS, CGB, EM, FM, BU, and ER are members of the Working group 1 (WG1) "Improve diagnosis and understanding of muscle pathology," MYO-MRI COST-Action (BM1304), "Applications of MR imaging and spectroscopy techniques in neuromuscular disease: collaboration on outcome measures and pattern recognition for diagnostics and therapy development".

F. Muntoni is supported by the National Institute of Health Research Biomedical Research Centre at Great Ormond Street Hospital for Children NHS Foundation Trust, and University College London. The support of Muscular Dystrophy UK and of the MRC Neuromuscular Translation Centre to the Dubowitz Neuromuscular Centre is also gratefully acknowledged.

AUTHOR CONTRIBUTIONS

GT, ER and CB conceived and designed the study. All the authors acquired and analyzed the data. GT, MM, and JDM drafted manuscript and figures. All the authors gave the final approval to the current version of the manuscript.

POTENTIAL CONFLICTS OF INTEREST

Nothing to report.

SUPPLEMENTARY MATERIAL

Supplementary table 1: Summary of clinical and genetic features of all the patients

Patient	Age at imaging	Sarcoglycanopathy (A/B/C/D)	Gender (M/F)	Ambulant (Y/N/N)	Side	Oblikui and transversi abdominis	Rectii abdominis	Quadratus femoris	Piriformis	Psoas	Obturator externus	Obturator internus	Tensor fasciae latae	Biceps	Paraspinal	Gluteus maximus	Gluteus medius	Gluteus minimus	Vastus lateralis	Vastus intermedius	Vastus medialis	Rectus femoris	Sartorius	Gracilis	Adductor longus	Adductor magnus	Adductor brevis	Adductor minimus	Semitendinosus	Semimembranosus	Biceps femoris, short head	Biceps femoris, long head	Tibialis anterior	Extensor hallucis and digitorum longus	Peroneal	Tibialis posterior	Flexor hallucis longus	Flexor digitorum longus	Popliteus	Soleus	Gastrocnemius medialis	Gastrocnemius lateralis	T1 MRI score
IT1_9	9	A	M	Y	R	0	0	0	0	0	0	0	0	0	0	0	0	0	0	0	0	0	0	0	0	0	0	0	0	0	0	0	0	0	0	0	0	0	0	0	0	0	0
					L	0	0	0	0	0	0	0	0	0	0	0	0	0	0	0	0	0	0	0	0	0	0	0	0	0	0	0	0	0	0	0	0	0	0	0	0	0	
CZ1_2	9	A	F	Y	R	0	0	0	0	0	0	0	0	0	0	0	0	0	0	0	0	0	0	0	0	0	0	0	0	0	0	0	0	0	0	0	0	0	0	0	0	0	0
					L	0	0	0	0	0	0	0	0	0	0	0	0	0	0	0	0	0	0	0	0	0	0	0	0	0	0	0	0	0	0	0	0	0	0	0	0	0	
IT1_10	10	A	F	Y	R	0	0	0	0	0	0	0	0	0	0	0	0	0	0	0	0	0	0	0	0	0	0	0	0	0	0	0	0	0	0	0	0	0	0	0	0	0	0
					L	0	0	0	0	0	0	0	0	0	0	0	0	0	0	0	0	0	0	0	0	0	0	0	0	0	0	0	0	0	0	0	0	0	0	0	0	0	
IT4_1	16	A	F	Y	R	0	0	0	0	0	0	0	0	0	0	0	0	0	0	0	0	0	0	0	0	0	0	0	0	0	0	0	0	0	0	0	0	0	0	0	0	0	0
					L	0	0	0	0	0	0	0	0	0	0	0	0	0	0	0	0	0	0	0	0	0	0	0	0	0	0	0	0	0	0	0	0	0	0	0	0	0	
IT5_4	16	G	F	Y	R	0	0	0	0	0	0	0	0	0	0	0	0	0	0	0	0	0	0	0	0	0	0	0	0	0	0	0	0	0	0	0	0	0	0	0	0	0	0
					L	0	0	0	0	0	0	0	0	0	0	0	0	0	0	0	0	0	0	0	0	0	0	0	0	0	0	0	0	0	0	0	0	0	0	0	0	0	
IT5_8	26	A	M	Y	R	0	0	0	0	0	0	0	0	0	0	0	0	0	0	0	0	0	0	0	0	0	0	0	0	0	0	0	0	0	0	0	0	0	0	0	0	0	0
					L	0	0	0	0	0	0	0	0	0	0	0	0	0	0	0	0	0	0	0	0	0	0	0	0	0	0	0	0	0	0	0	0	0	0	0	0	0	
DN2_1	5	B	M	Y	R	na	na	na	na	na	na	na	na	na	na	na	na	na	0	0	0	0	0	0	0	1	0	0	0	0	0	0	0	0	0	0	0	0	0	0	0	0	4
					L	na	na	na	na	na	na	na	na	na	na	na	na	na	0	0	0	0	0	0	0	1	0	0	0	0	0	0	0	0	0	0	0	0	0	0	0	0	
US1_2	6	B	M	Y	R	0	0	0	0	0	0	0	0	0	0	1	0	0	0	0	0	0	0	0	0	1	0	0	0	0	0	0	0	0	0	0	0	0	0	0	0	0	5
					L	0	0	0	0	0	0	0	0	0	0	1	0	0	1	0	0	0	0	0	0	1	0	0	0	0	0	0	0	0	0	0	0	0	0	0	0	0	
US1_3	7	G	M	Y	R	0	0	0	0	0	0	0	0	0	0	1	0	0	1	0	0	0	0	0	0	1	0	0	0	0	0	0	0	0	0	0	0	0	0	0	0	0	5
					L	0	0	0	0	0	0	0	0	0	0	1	0	0	0	0	0	0	0	0	0	1	0	0	0	0	0	0	0	0	0	0	0	0	0	0	0	0	
IT3_1	4	A	F	Y	R	0	0	0	0	0	0	0	0	0	0	1	1	0	0	0	0	0	0	0	0	1	0	0	0	0	0	0	0	0	0	0	0	0	0	0	0	0	6
					L	0	0	0	0	0	0	0	0	0	0	1	1	0	0	0	0	0	0	0	0	1	0	0	0	0	0	0	0	0	0	0	0	0	0	0	0	0	
DS2_3	4	G	F	Y	R	0	0	0	0	0	0	0	0	0	0	1	0	1	0	0	0	0	0	0	0	0	0	1	0	0	0	0	0	0	0	0	0	0	0	0	0	0	7
					L	0	0	0	0	0	0	0	0	0	0	1	0	1	0	0	0	0	0	0	0	1	0	1	0	0	0	0	0	0	0	0	0	0	0	0	0	0	
IT5_7	15	A	M	Y	R	0	0	0	0	1	0	0	0	0	0	0	1	1	1	0	0	0	0	0	0	1	0	0	0	0	0	0	0	0	0	0	0	0	0	0	0	0	18
					L	0	0	0	0	1	0	0	0	0	0	0	1	1	1	0	0	0	0	0	0	1	0	0	0	0	0	0	0	0	0	0	0	0	0	0	0	0	
IT5_1	9	B	M	Y	R	0	0	0	0	0	0	1	0	0	0	1	1	0	1	0	0	0	0	0	0	1	1	1	0	0	0	1	0	0	0	0	0	0	0	0	0	0	29
					L	0	0	0	0	0	0	1	0	0	0	1	1	0	1	0	0	0	0	0	0	1	1	1	0	1	0	1	0	0	0	0	0	0	0	0	1	0	
RU1_1	6	A	M	Y	R	0	0	0	1	1	1	1	0	0	0	na	1	0	1	1	0	0	1	1	1	1	1	1	0	0	0	1	0	0	0	0	0	0	0	0	0	0	44
					L	0	0	0	1	1	1	1	0	0	0	na	1	0	0	1	0	0	0	1	1	1	1	1	0	0	0	1	0	0	0	0	0	0	0	0	0	0	
IT2_1	19	A	F	Y	R	na	na	1	na	0	0	1	0	na	na	na	na	na	1	1	1	0	0	0	1	1	1	1	1	0	0	1	0	0	0	0	0	0	0	0	0	0	46
					L	na	na	1	na	0	0	1	0	na	na	na	na	na	1	1	1	0	0	0	1	1	1	1	1	0	0	1	0	0	0	0	0	0	0	0	0	0	0	
IT1_6	8	A	M	Y	R	0	0	1	2	2	0	0	1	0	0	1	1	1	2	1	2	1	0	0	2	1	1	2	0	1	0	1	0	0	0	0	0	0	0	0	0	0	63
					L	0	0	1	1	1	0	0	0	0	0	1	1	1	1	1	1	0	0	0	1	1	1	1	0	1	0	1	0	0	0	0	0	0	0	0	0	0	
DS1_5	17	A	F	Y	R	2	0	1	1	0	1	0	0	0	1	1	1	1	1	0	0	0	0	0	1	1	1	1	0	1	0	1	0	0	0	0	0	0	0	0	0	0	65
					L	1	0	1	1	0	2	0	0	0	0	1	0	1	1	0	0	0	0	0	1	1	1	1	0	1	0	1	0	0	0	0	0	0	0	0	0	0	
IT5_3	19	A	F	Y	R	1	0	1	1	0	0	1	0	0	1	2	1	1	1	0	0	0	0	0	2	1	2	2	0	0	0	2	0	0	0	0	0	0	0	0	0	0	71
					L	1	0	1	1	0	1	1	0	0	0	1	0	0	0	0	0	0	0	0	1	1	1	1	0	1	0	1	0	0	0	0	0	0	0	0	0	0	
IT1_11	14	A	F	Y	R	1	0	1	1	0	2	1	0	0	1	2	1	1	0	0	0	0	0	0	1	1	1	1	0	1	0	1	0	0	0	0	0	0	0	0	0	0	73
					L	1	0	1	1	0	1	1	0	0	1	2	1	1	0	0	0	0	0	0	1	1	2	2	0	1	0	1	0	0	0	0	0	0	0	0	0	0	
US1_1	9	B	F	Y	R	1	0	0	1	1	1	1	0	0	2	2	2	1	2	2	2	1	0	0	1	1	1	1	0	0	0	1	0	0	1	0	0	0	0	0	0	0	89
					L	1	0	0	1	1	1	1	0	0	2	2	1	1	2	2	2	1	0	0	1	1	1	1	0	0	0	1	0	0	0	0	0	0	0	0	0	0	
DN2_2	14	G	M	Y	R	na	na	na	na	na	na	na	na	0	na	na	na	na	na	2	2	1	1	0	0	1	1	1	1	1	2	1	2	0	0	0	0	0	0	0	1	0	0	63
					L	na	na	na	na	na	na	na	na	1	na	na	na	na	na	2	1	1	0	0	0	1	1	1	0	0	1	0	1	0	0	0	0	0	0	0	1	0	0	
IT1_8	19	A	F	Y	R	1	1	2	2	0	1	1	1	0	1	1	1	1	1	1	1	1	0	0	1	1	1	1	0	1	0	1	0	0	0	0	0	0	0	0	0	0	##
					L	1	1	2	1	0	1	1	1	0	1	1	1	1	1	1	2	1	0	0	1	1	1	1	0	1	0	1	0	0	0	0	0	0	0	0	0	0	
DS1_3	27	A	F	Y	R	0	0	1	1	1	1	1	0	0	1	1	1	1	2	1	2	1	0	0	1	1	1	1	0	1	0	1	0	0	0	0	0	0	0	0	0	0	##
					L	0	0	1	1	1	1	1	0	0	1	1	1	1	2	1	1	1	0	0	1	1	1	1	0	0	0	1	0	0	0	0	0	0	0	0	0	0	
IT2_3	16	A	M	Y	R	0	0	1	1	1	1	1	1	0	na	1	1	1	2	1	2	1	0	0	1	1	1	1	0	0	0	1	0	0	0	0	0	0	0	0	0	0	##
					L	0	0	1	1	1	1	1	0	0	na	1	1	1	2	1	1	1	0	0	1	1	1	1	0	1	0	1	0	0	0	0	0	0	0	0	0	0	
IT1_3	11	G	F	Y	R	1	0	na	1	1	1	1	1	1	1	1	1	1	2	1	2	1	0	0	1	1	1	1	0	0	0	1	0	0	0	0	0	0	0	0	1	0	##
					L	1	0	na	1	1	1	1	1	1	1	1	1	1	2	1	1	1	0	0	1	1	1	1	0	0	0	1	0	0	0	0	0	0	0	0	1	0	
IT3_9	11	A	M	Y	R	1	1	1	1	1	1	1	1	0	1	1	1	1	2	1	2	1	1	0	1	1	1	1	1	1	1	1	1	0	0	0	0	0	0	0	0	0	##
					L	1	1	1	1	1	1	1	1	0	1	1	1	1	2	1	1	1	0	0	1	1	1	1	1	1	1	1	1	0	0	0	0	0	0	0	0	0	
DS2_2	11	G	F	Y	R	1	0	1	1	1	1	1	1	0	1	1	1	1	2	1	2	1	1	0	1	1	1	1	1	1	1	1	1	0	0	0	0	0	0	0	0	0	##
					L	1	0	1	1	1	1	1	1	0	0	1	1	1	1	1	1	1	0	0	1	1	1	1	1	1	1	1	1	0	1	0	0	0	0	0	0	0	
IT3_3	24	A	M	Y	R	na	na	1	1	1	1	1	1	0	1	na	1	1	1	2	1	1	0	0	1	1	1	1	1	1	2	1	1	0	0	0	0	0	0	0	0	0	##
					L	na	na	1	1	1	1	1	1	0	1	na	1	1	1	2	1	1	0	0	1	1	1	1	1	1	1	1	1	0	0	0	0	0	0	0	0	0	
IT3_2	7	A	M	Y	R	1	0	1	1	1	1	1	1	0	1	1	1	1	2	1	1	1	0	0	1	1	1	1	1	1	1	1	1	0	0	0	0	0	0	0	1	0	##
					L	1	0	1	1	1	1	1	1	0	0	1	1	1	1	1	1	1	0	0	1	1	1	1	1	1	1	1	1	0	0	0	0	0	0	0	0	0	
DN3_3	19	A	M	Y	R	1	1	1	1	1	1	1	1	0	1	1	1	1	2	1	1	1	0	0	1	1	1	1	1	1	1	1	1	0	0	0	0	0	0	0	0	0	##
					L	1	1	1	1	1	1	1	1	0	1	1	1	1	2	1	1	1	0	0	1	1	1	1	1	1	1	1	1	0	0	0	0	0	0	0	0	0	
CZ1_3	8	G	F	Y	R	1	0	1	1	1	1	1	2	0	2	1	1	1	2	1	1	2	1	1	1	1	1	1	1	1	1	1	1	1	1	1	0	0	0	0	1	1	##
					L	1	1	1	1	1	1	1	1	0	1	1	1	1	1	1	1	1	1	1	1	1	1	1	1	1	1	1	0	1	1	0	0	0	0	1	1	
PR1_2	10	A	M	Y	R	2	0	1	1	1	1	1	0	0	1	1	1	1	1	1	1	2	0	0	1	1	1	1	1	1	1	1	1	1	1	0	0	0	0	0	0	0	##
					L	1	0	1	1	1	1	1	0	0	1	1	1	1	1	1	1	1	0	0	1	1	1	1	1	1	1	1	1	0	0	0	0	0	0	0	0	0	
DS1_4	49	A	F	Y	R	1	1	1	1	1	1	1	0	0	1	1	1	1	2	1	2	1	0	0	1	1	1	1	1	1	1	1	1	0	0	0	0	0	0	0	0	0	##
					L	1	1	1	1	0	1	1	0	0	1	1	1	1	2	1	2	1	0	0	1	1	1	1	1	1	1	1	1	0	0	0	0	0	0	0	0	0	
IT3_4	20	B	F	Y	R	1	0	1	1	1	1	1	1	1	1	1	1	1	2	1	2	2	0	0	1	1	1	1	1	1	1	1	1	1	0	0	0	0	0	0	0	0	##
					L	1	0	1	1	1	1	1	1	1	1	1	1	1	2	1	2	2	0	0	1	1	1	1	1	1	1	1	1	1	0	0	0	0	0	0	0	0	
IT3_5	15	B	F	Y	R	1	0	1	1	1	1	1	1	1	na	1	1	1	2	1	2	1	0	0	1	1	1	1	1	1	1	1	1	0	0	0	0	0	0	0	0	0	##
					L	1	0	1	1	1	1	1	1	1	na	1	1	1	1	1	1	2	0	0	1	1	1	1	1	1	1	1	1	0	0	0	0	0	0	0	0	0	
DN3_1	41	G	M	Y-G	R	1	1	1	1	1	1	1	2	1	1	1	1	1	2	1	1	1	1	0	1	1	1	1	1	1	1	1	1	0	0	0	0	0	0	0	1	1	##
					L	1	1	1	1	1	1	1	1	1	na	1	1	1	1	1	1	1	0	1	1	1	1	1	1	1	1	1	0	0	0	0	0	0	0	0	0	0	
DS1_6	51	A	F	Y	R	1	0	1	1	1	1	1	1	1	1	1	1	1	2	1	2	1	1	0	1	1	1	1	1	1	1	1	1	0	0	0	0	0	0	0	0	0	##
					L	1	0	1	1	1	1	1	0	1	1	1	1	1	1	1	1	1	0	0	1	1	1	1	1	1	1	1	0	0	0	0	0	0	0	0	0	0	
IT1_1	34	A	M	Y	R	1	1	1	1	1	1	1	2	1	1	1	1	1	2	1	2	0	0	0	1	1	1	1	1	1	1	1	1	0	1	0	0	0	0	0	0	0	##
					L	1	1	1	1	1	1	1	2	1	1	1	1	1	2	1	2	0	0	0	1	1	1	1	1	1	1	1	0	1	0	0	0	0	0	0	0	0	
IT5_6	19	A	F	Y-G	R	1	1	1	1	1	1	1	0	1	1	1	1	1	1	1	1	1	0	0	1	1	1	1	1	1	1	1	1	0	1	0	0	0	0	0	1	0	##
					L	1	1	1	1	1	1	1	1	1	1	1	1	1	0	0	1	1	0	0	1	1	1	1	1	1	1	1	0	0	0	0	0	0	0	0	0	0	
IT1_2	10	G	M	Y	R	1	1	1	1	1	1	1	1	1	1	1	1	1	2	1	2	1	0	0	1	1	1	1	1	1	1	1	1	0	1	0	0	0	0	0	0	0	##
					L	1	1	1	1	1	1	1	1	1	1	1	1	1	2	1	2	1	0	0	1	1	1	1	1	1	1	1	0	2	0	0	0	0	0	0	0	0	
IT4_1	11	B	M	N	R	1	0	1	1	1	1	1	1	1	na	1	1	1	2	1	2	1	0	0	1	1	1	1	1	1	1	1	1	1	1	0	0	0	1	1	1	1	##
					L	1	0	1	1	1	1	1	1	1	na	1	1	1	1	1	1	1	0	0	1	1	1	1	1	1	1	1	0	1	0	0	0	1	1	1	1	1	
IT4_6	12	A	F	Y	R	1	0	1	1	1	1	1	1	0	1	1	1	1	2	1	2	1	0	1	1	1	1	1	1	1	1	1	1	0	1	0	1	1	1	1	1	1	##
					L	1	0	1	1	1	1	1	1	0	1	1	1	1	2	1	2	1	0	1	1	1	1	1	1	1	1	1	0	1	0	0	0	1	1	1	1	1	
IT1_7	9	G	F	Y	R	1	1	1	1	1	1	1	2	1	1	1	1	1	2	1	2	1	1	1	1	1	1	1	1	1	1	1	1	1	1	0	0	0	1	1	1	1	##
					L	1	1	1	1	1	1	1	1	1	1	1	1	1	2	1	2	1	1	1	1	1	1	1	1	1	1	1	0	1	0	0	0	1	1	1	1	1	
DN3_2	36	B	M	Y	R	1	1	1	1	1	1	1	1	1	1	1	1	1	2	1	2	1	0	1	1	1	1	1	1	1	1	1	1	0	0	0	0	0	0	0	0	0	##
					L	1	1	1	1	1	1	1	1	1	1	1	1	1	2	1	2	1	1	1	1	1	1	1	1	1	1	1	0	0	0	0	0	0	0	0	0	0	
DS1_3	11	A	M	Y	R	1	1	1	1	1	1	1	1	1	1	1	1	1	2	1	2	1	1	1	1	1	1	1	1	1	1	1	1	1	1	0	1	0	0	0	1	1	##
					L	1	1	1	1	1	1	1	1	1	1	1	1	1	2	1	2	1	1	1	1	1	1	1	1	1	1	1	0	1	0	0	0	0	0	1	1	0	
IT4_5	8	B	M	Y	R	1	1	1	1	1	1	1	1	1	na	1	1	1	2	1	2	1	0	1	1	1	1	1	1	1	1	1	1	1	1	0	1	0	0	1	1	1	##
					L	1	1	1	1	1	1	1	1	1	na	1	1	1	1	1	1	1	0	1	1	1	1	1	1	1	1	1	0	1	0	0	0	0	0	0	0	0	
DS2_1	30	B	M	Y	R	1	1	1	1	1	1	1	1	1	1	1	1	1	2	1	2	1	1	1	1	1	1	1	1	1	1	1	1	0	1	0	0	0	0	0	1	0	##
					L	1	1	1	1	1	1	1	1	1	1	1	1	1	2	1	2	1	1	1	1	1	1	1	1	1	1	1	0	1	0	0	0	0	0	1	0	0	
DS1_1	36	A	M	Y-G	R	1	1	1	1	1	1	1	1	1	1	1	1	1	2	1	2	1	0	1

Supplementary table 2: Scoring of all the muscles.

CentreID and PtID (sex)	Molecular genetics (mutation)	Age at onset – symptom(s) at onset (years)	Age
IT1_1 (M)	SGCA [c.229C>T/p.R77C] + [c.739G>A/p.V247M]	13, difficulties in running	
IT1_2 (M)	SGCG [c.342dupT/p.A115CfsX41] + [c.525delT/p.F175LfsX20]	4, difficulties in running	
IT1_3 (F)	SGCG [c.525delT/p.F175LfsX20] + [c.525delT/p.F175LfsX20]	4, difficulties in running	
IT1_4 (F)	SGCG [c.525delT/p.F175LfsX20] + [c.525delT/p.F175LfsX20]	15, difficulties in climbing stairs	
IT1_5 (F)	SGCA [c.229C>T/p.R77C] + [c.850C>T/p.R284C]	3rd decade, difficulties in climbing stairs	
IT1_6 (M)	SGCA [c.308T>C/p.I103T] + [c.480dupC/p.L164TfsX27]	hyperCKemia at age 2, difficulties in climbing stairs at age 5	
IT1_7 (F)	SGCG [c.525delT/p.F175LfsX20] + [c.525delT/p.F175LfsX20]	hyperCKemia at age 2, toe walking at age 6	
IT1_8 (F)	SGCA [c.308T>C/p.I103T] + [c.850C>T/p.R284C]	12, myalgias and exercise intolerance	
IT1_9 (M)*	SGCA [c.229C>T/p.R77C] + [c.739G>A/p.V247M]	6, asymptomatic hyperCKemia	
IT1_10 (F)*	SGCA [c.229C>T/p.R77C] + [c.739G>A/p.V247M]	10, asymptomatic hyperCKemia	
IT1_11 (F)	SGCA [c.850C>T/p.R284C] + [c.850C>T/p.R284C]	45, hyperCKemia	
IT2_1 (F)	SGCA [c.739G>A/p.V247M] + [c.739G>A/p.V247M]	11, hyperCKemia, post-exercise muscle pain and myoglobinuria	
IT2_3 (M)	SGCA [c.850C>T/p.R284C] + [c.850C>T/p.R284C]	10, hyperCKemia, post-exercise muscle pain	
IT3_1 (F)	SGCA [c.229C>T/p.R77C] + ?	4, difficulties in running	
IT3_2 (M)	SGCA [c.89del/p.P30HfsX17] + [c.89del/p.P30HfsX17]	4,difficulties in running	
IT3_3 (M)	SGCA [c.409G>A/p.E137K] + [c.739G>A/p.V247M]	8, difficulties in climbing stairs	
IT3_4 (F)#	SGCB [c.265G>A/p.V89M] + [c.265G>A/p.V89M]	9, difficulties in running	
IT3_5 (F)#	SGCB [c.265G>A/p.V89M] + [c.265G>A/p.V89M]	9, difficulties in running and climbing stairs	
IT3_6 (M)	SGCA [c. 229C>T/p.R77C] + [c.1005C>A/p.C335X]	9, difficulties in running and climbing stairs	
IT3_7 (M)	SGCG [c.801_802del/p.P268RfsX48] + [c.385+2T>C/p.?]	7, difficulties in running and climbing stairs	
IT3_8 (M)	SGCD [c.465_469del .Q118fs+2X17] + [c.465_469del p.Q118fs+2X17]	4, difficulties in running and climbing stairs	
IT3_9 (M)	SGCA [c.92T>C/p.L31P] + [c.92T>C/p.L31P]	3, toe walking	
IT4_1 (M)^	SGCB [c.377_384dup/p.G129QfsX2] + [c.377_384dup/p.G129QfsX2]	3, walking difficulties	
IT4_3 (F)	SGCA [c.739G>A/p.V247M] + [c.739G>A/p.V247M]	9 , myalgia, high CK	
IT4_4 (M)	SGCG [c.525delT/p.F175LfsX20] + [c.525delT/p.F175LfsX20]	7, high CK, walking difficulties	
IT4_5 (M)^	SGCB [c.377_384dup/p.G129QfsX2] + [c.377_384dup/p.G129QfsX2]	2, walking difficulties	
IT4_6 (F)	SGCA [c.271G>A/p.G91S] + [c.292 C>T/p.R98C]	3, proximal weakness	
IT5_1 (M)	SGCB [c.377_384dup/T126RfsX5] + [c.377_384dup/T126RfsX5]	4, difficulties in running, early fatigue	
IT5_2 (F)	SGCG [c.87dup/p.G30WfsX30] + [c.87dup/p.G30WfsX30]	6, proximal lower limb weakness	
IT5_3 (F)	SGCA [c.739G>A/p.Val247Met] + [c.739G>A/p.Val247Met]	38, exertional pain	
IT5_4 (F)	SGCG [c.371G>A/p.G124D] + [c.371G>A/p.G124D]	6, myalgias	
IT5_5 (F)	SGCB [c.552T>G/p.Y184X] + [c.552T>G/p.Y184X]	5, running difficulaties, proximal lower limb weakness	
IT5_6 (F)§	SGCA [c.850C>T/p.R284C] + [c.850C>T/p.R284C]	20, walking difficulties	
IT5_7 (M)§	SGCA	Asymptomatic	

FUNDING

No specific funding was used for this work.

REFERENCES

1. Mercuri E, Muntoni F. Muscular dystrophies. *Lancet* 2013;381:845-60.
2. Marsolier J, Laforet P, Pegoraro E, Vissing J, Richard I, Sarcoglycanopathies WG. 1st International Workshop on Clinical trial readiness for sarcoglycanopathies 15-16 November 2016, Evry, France. *Neuromuscul Disord* 2017. doi: 10.1016/j.nmd.2017.02.011
3. Angelini C, Fanin M. Pathogenesis, clinical features and diagnosis of sarcoglycanopathies. *Expert Opinion on Orphan Drugs* 2016. doi:10.1080/21678707.2016.1256769
4. Klinge L, Dekomien G, Aboumousa A *et al.* Sarcoglycanopathies: can muscle immunoanalysis predict the genotype? *Neuromuscul Disord* 2008;18:934-41.
5. Trabelsi M, Kavian N, Daoud F *et al.* Revised spectrum of mutations in sarcoglycanopathies. *Eur J Hum Genet* 2008;16:793-803.
6. Fanin M, Nascimbeni AC, Aurino S *et al.* Frequency of LGMD gene mutations in Italian patients with distinct clinical phenotypes. *Neurology* 2009;72:1432-5.
7. Wattjes MP, Kley RA, Fischer D. Neuromuscular imaging in inherited muscle diseases. *Eur Radiol* 2010;20:2447-60.
8. Tasca G, Monforte M, Ottaviani P *et al.* Magnetic Resonance Imaging in a large cohort of facioscapulohumeral muscular dystrophy patients: pattern refinement and implications for clinical trials. *Ann Neurol* 2016. doi: 10.1002/ana.24640
9. Tasca G, Monforte M, De Fino C, Kley RA, Ricci E, Mirabella M. Magnetic resonance imaging pattern recognition in sporadic inclusion-body myositis. *Muscle Nerve* 2015;52:956-62.
10. Lodi R, Muntoni F, Taylor J *et al.* Correlative MR imaging and 31P-MR spectroscopy study in sarcoglycan deficient limb girdle muscular dystrophy.

Neuromuscul Disord 1997;7:505-11.

11. Straub V, Carlier PG, Mercuri E. TREAT-NMD workshop: pattern recognition in genetic muscle diseases using muscle MRI: 25-26 February 2011, Rome, Italy. *Neuromuscul Disord* 2012;22 Suppl 2:S42-53.
12. Eymard B, Romero NB, Leturcq F *et al.* Primary adhalinopathy (alpha-sarcoglycanopathy): clinical, pathologic, and genetic correlation in 20 patients with autosomal recessive muscular dystrophy. *Neurology* 1997;48:1227-34.
13. Fischer D, Walter MC, Kesper K *et al.* Diagnostic value of muscle MRI in differentiating LGMD2I from other LGMDs. *J Neurol* 2005;252:538-47.
14. van der Kooi AJ, de Visser M, van Meegen M *et al.* A novel gamma-sarcoglycan mutation causing childhood onset, slowly progressive limb girdle muscular dystrophy. *Neuromuscul Disord* 1998;8:305-8.
15. ten Dam L, van der Kooi AJ, van Wattingen M, de Haan RJ, de Visser M. Reliability and accuracy of skeletal muscle imaging in limb-girdle muscular dystrophies. *Neurology* 2012;79:1716-23.
16. Tasca G, Ricci E, Monforte M *et al.* Muscle imaging findings in GNE myopathy. *J Neurol* 2012;259:1358-65.
17. Fischer D, Kley RA, Strach K *et al.* Distinct muscle imaging patterns in myofibrillar myopathies. *Neurology* 2008;71:758-65.
18. Díaz-Manera J, Alejaldre A, González L *et al.* Muscle imaging in muscle dystrophies produced by mutations in the EMD and LMNA genes. *Neuromuscul Disord* 2016;26:33-40.
19. Magri F, Nigro V, Angelini C *et al.* The italian limb girdle muscular dystrophy registry: Relative frequency, clinical features, and differential diagnosis. *Muscle Nerve* 2017;55:55-68.

20. Tasca G, Iannaccone E, Monforte M *et al.* Muscle MRI in Becker muscular dystrophy. *Neuromuscul Disord* 2012;22 Suppl 2:S100-6.

21. Tasca G, Monforte M, Iannaccone E *et al.* Muscle MRI in female carriers of dystrophinopathy. *Eur J Neurol* 2012;19:1256-60.

22. Tasca G, Moro F, Aiello C *et al.* Limb-girdle muscular dystrophy with alpha-dystroglycan deficiency and mutations in the ISPD gene. *Neurology* 2013;80:963-5.

23. Díaz-Manera J, Llauger J, Gallardo E, Illa I. Muscle MRI in muscular dystrophies. *Acta Myol* 2015;34:95-108.

24. Mercuri E, Clements E, Offiah A *et al.* Muscle magnetic resonance imaging involvement in muscular dystrophies with rigidity of the spine. *Ann Neurol* 2010;67:201-8.

25. Sandell SM, Mahjneh I, Palmio J, Tasca G, Ricci E, Udd BA. 'Pathognomonic' muscle imaging findings in DNAJB6 mutated LGMD1D. *Eur J Neurol* 2013;20:1553-9.

26. Carlier RY, Laforet P, Wary C *et al.* Whole-body muscle MRI in 20 patients suffering from late onset Pompe disease: Involvement patterns. *Neuromuscul Disord* 2011;21:791-9.

27. Monforte M, Mercuri E, Laschena F, Ricci E, Tasca G. Calf muscle involvement in Becker muscular dystrophy: when size does not matter. *J Neurol Sci* 2014;347:301-4.

FIGURE LEGENDS

Figure 1. PROGRESSIVE MUSCLE INVOLVEMENT IN SARCOGLYCANOPATHIES.

A) Early involvement is noticeable in adductor magnus (arrow), with milder concomitant changes in gluteus maximus and minimus. B) and C) At later stages, glutei muscles become involved as well as proximal quadriceps and posterior thigh. Lower leg remains spared even when the thigh and pelvis are significantly affected, and sartorius and gracilis (arrow and arrowhead) may show relative hypertrophy. D) In most advanced patients, there is severe diffuse muscle involvement with selective sparing of flexor digitorum longus and tibialis posterior (arrowhead), and of a rim of the distal vastus lateralis (arrow). A) ES2_3 (age 4, LGMD2C), B) IT3_9 (age 11, LGMD2D), C) IT1_1 (age 34, LGMD2D), D) FI1_3 (age 35, LGMD2D).

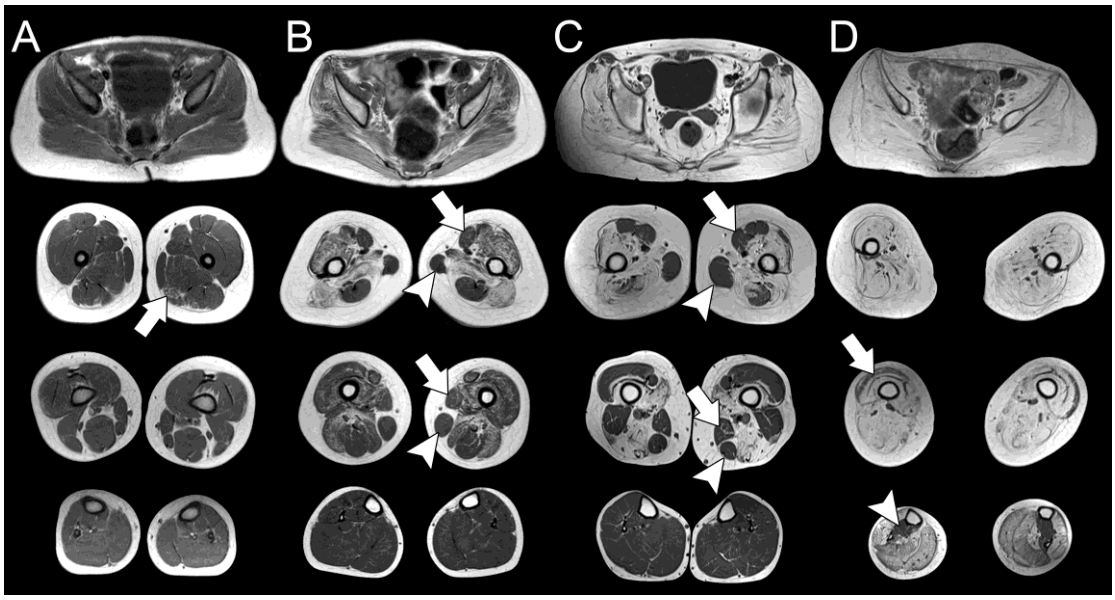

Figure 2. SUMMARY OF PELVIC AND LOWER LIMB MUSCLE INVOLVEMENT IN SARCOGLYCANOPATHY PATIENTS.

A) Frequency of involvement of the different muscles, grouped by body region, is expressed as a percentage of the total. Green bars indicate the percentage of muscles affected with each specified score. The numbers in square brackets represent the median score for each muscle. B) Heatmap showing the hierarchical clustering of patients and muscles according to the scores given to the single muscles. Patients do not cluster according to their molecular diagnosis but rather to the severity of involvement.

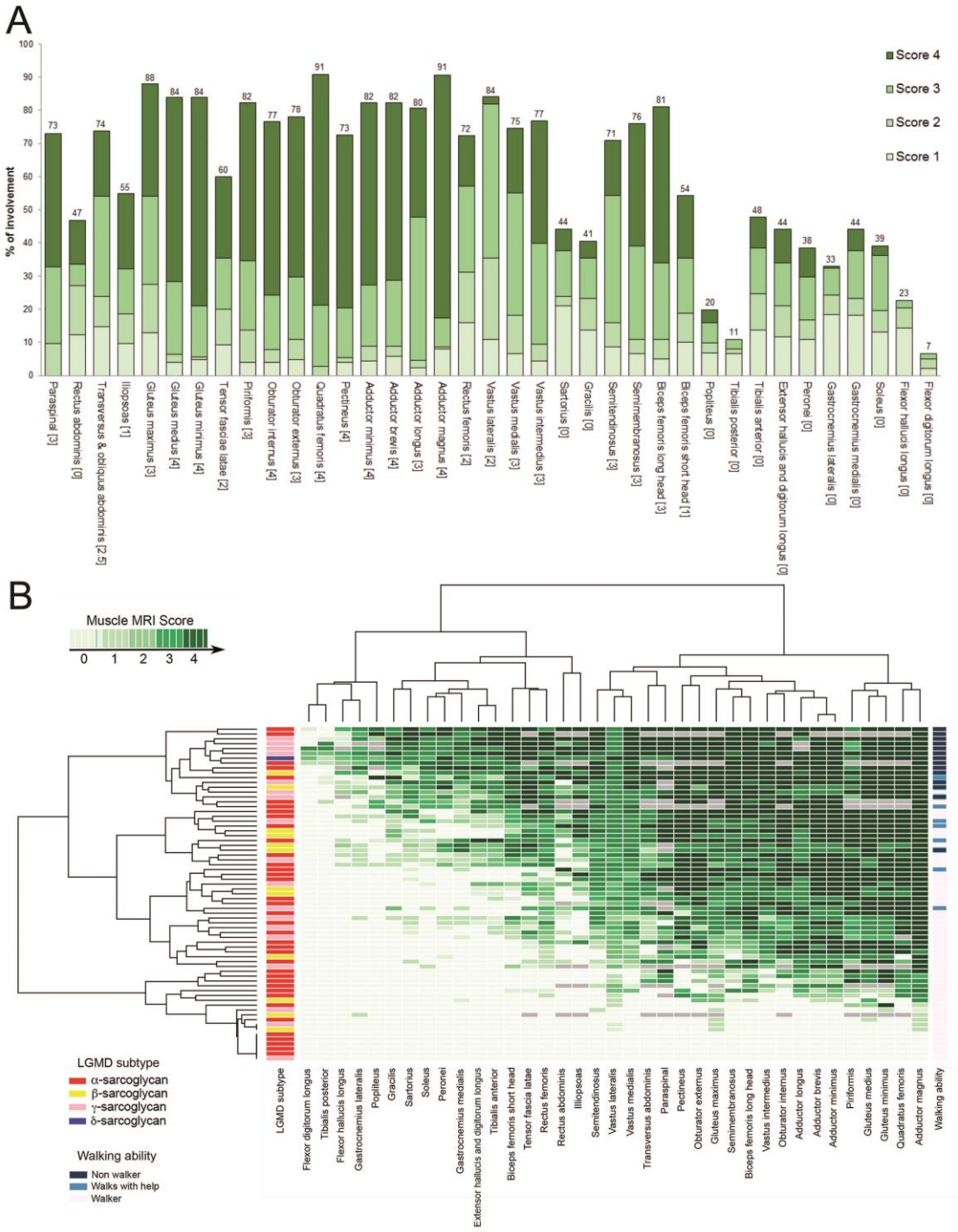
A
% of involvement
Score 4
Score 3
Score 2
Score 1
Paraspinal [3]
Rectus abdominis [0]
Transversus & obliquus abdominis [2.5]
Iliopsoas [1]
Gluteus maximus [3]
Gluteus medius [4]
Gluteus minimus [4]
Tensor fasciae latae [2]
Piriformis [3]
Obturator internus [4]
Obturator externus [3]
Quadratus femoris [4]
Pectineus [4]
Adductor minimus [4]
Adductor brevis [4]
Adductor longus [3]
Adductor magnus [4]
Rectus femoris [2]
Vastus lateralis [2]
Vastus medialis [3]
Vastus intermedius [3]
Sartorius [0]
Gracilis [0]
Semitendinosus [3]
Semimembranosus [3]
Biceps femoris long head [3]
Biceps femoris short head [1]
Popliteus [0]
Tibialis posterior [0]
Tibialis anterior [0]
Extensor hallucis and digitorum longus [0]
Peronei [0]
Gastrocnemius lateralis [0]
Gastrocnemius medialis [0]
Soleus [0]
Flexor hallucis longus [0]
Flexor digitorum longus [0]
B
Muscle MRI Score
0 1 2 3 4
LGMD subtype
α-sarcoglycan
β-sarcoglycan
γ-sarcoglycan
δ-sarcoglycan
Walking ability
Non walker
Walks with help
Walker
LGMD subtype
Flexor digitorum longus
Tibialis posterior
Flexor hallucis longus
Gastrocnemius lateralis
Popliteus
Gracilis
Sartorius
Soleus
Peronei
Gastrocnemius medialis
Extensor hallucis and digitorum longus
Tibialis anterior
Biceps femoris short head
Tensor fascia latae
Rectus femoris
Rectus abdominis
Iliopsoas
Semitendinosus
Vastus lateralis
Vastus medialis
Transversus abdominis
Paraspinal
Pectineus
Obturator externus
Gluteus maximus
Semimembranosus
Biceps femoris long head
Vastus intermedius
Obturator internus
Adductor longus
Adductor brevis
Adductor minimus
Piriformis
Gluteus medius
Gluteus minimus
Quadratus femoris
Adductor magnus
Walking ability

Figure 3. PATTERN RECOGNITION AND "GESTALTIC" CRITERIA.

A), B) and C) Two consistent features are the proximo-distal gradient of involvement of the vastus lateralis, with the typical proximal fatty replacement close to the femur head (arrow), and the distal sparing even in the most severely affected patients (arrowheads). D), E) and F) Adductor longus also shows peculiar involvement with sparing of the most medial fascicles (arrows). A) US1_1 (age 9, LGMD2E), B) IT3_5 (age 15, LGMD2E), C) IT1_4 (age 50, LGMD2C), D) CZ1_1 (age 8, LGMD2C), E) IT1_2 (age 10, LGMD2), F) IT2_1 (age 29, LGMD2D).

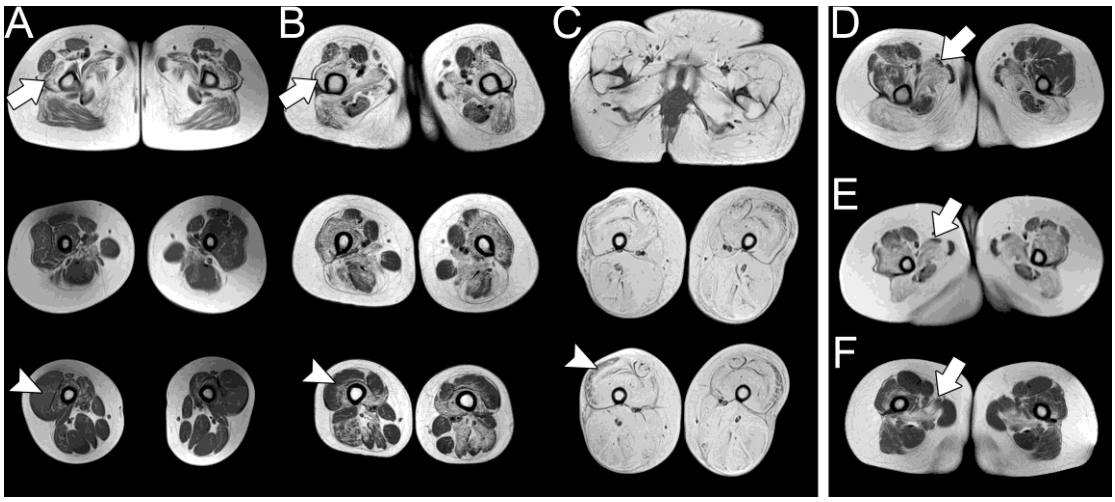

Figure 4. EXAMPLES OF INVOLVEMENT AT PELVIS, THIGH AND LOWER LEG LEVEL IN THE DIFFERENT SARCOGLYCANOPATHIES.

A similar pattern is shared by the different sarcoglycanopathies. IT1_2, LGMD2C; IT3_3, LGMD2D; IT3_4, LGMD2E; IT3_8, LGMD2F.

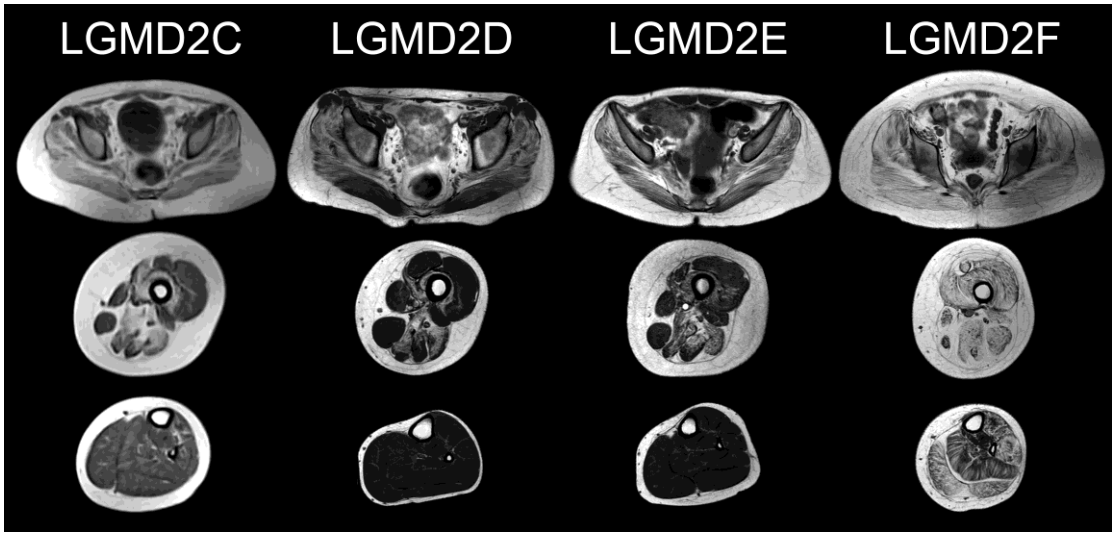
LGMD2C
LGMD2D
LGMD2E
LGMD2F

Table 1. "GESTALTIC" CRITERIA

Criteria	
Quadriceps gradient	58/58* (100 %)
Relative sparing of tibialis posterior and flexor digitorum longus	66/69 (96 %)
Adductor longus medial sparing	41/56* (73 %)
Normal or almost normal leg	45/69 (65 %)
Relative sparing of tensor fasciae latae	41/69 (59 %)
Hypertrophy of either sartorius or gracilis	24/69 (35 %)

* In the remaining patients the feature could not be assessed because of total muscle sparing or incomplete scans.